

# Comparing Laser and Scalpel for Soft Tissue Crown Lengthening: A Clinical Study

Sana Farista<sup>1</sup>, Butchibabu Kalakonda<sup>2</sup>, Pradeep Koppolu<sup>2</sup>, Kusai Baroudi<sup>2</sup>, Esam Elkhata<sup>2</sup> & Essam Dhaifullah<sup>2</sup>

<sup>1</sup> Department of Periodontics, Maitri Dental College, Chhattisgarh, India

<sup>2</sup> Department of Preventive Dental Sciences, Al Farabi Colleges, Riyadh, KSA

Correspondence: Butchibabu Kalakonda, Department of Preventive Dental Sciences, Al Farabi Colleges, Riyadh, KSA. Tel: 96-65-9079-8400. E-mail: docbutchi@gmail.com

Received: December 19, 2015 Accepted: February 16, 2016 Online Published: February 24, 2016

doi:10.5539/gjhs.v8n10p73

URL: <http://dx.doi.org/10.5539/gjhs.v8n10p73>

## Abstract

Crown lengthening procedure is aimed at exposure of sufficient crown structure accomplished by a gingivectomy, an apically positioned flap with osseous resection or the use of lasers. Our present clinical study is aimed to assess the clinical effectiveness of a diode laser for functional crown lengthening procedure and to compare it with the conventional procedure using the scalpel. Fourteen patients including males and females, aged 20- 40 years were recruited and divided into two groups to undergo crown lengthening either with the scalpel or the laser. The data obtained was analyzed for intergroup comparison with an Unpaired t-test and intragroup comparison was determined by ANOVA.

Analysis of the intergroup results for pain showcased that there was a significant difference ( $P < 0.002$ ) in VAS scores of pain on the 3<sup>rd</sup> day as well as on the 7<sup>th</sup> day ( $P < 0.044$ ), with patients in the laser group displaying significantly lower VAS scores compared to the scalpel group, but when both the groups were compared on the 10<sup>th</sup> day, there was no significance ( $P < 0.14$ ).

Intergroup comparison of the mean VAS scores for discomfort observed on the 3<sup>rd</sup>, 7<sup>th</sup> and the 10<sup>th</sup> day of the study suggested that there was a significant difference of the VAS scores of discomfort on the 3<sup>rd</sup> and the 7<sup>th</sup> days, with the patients in the laser group displaying significantly lower VAS scores for discomfort compared with the scalpel.

Observations from the study emphasize that laser can be a safe and effective alternative to traditional crown lengthening performed with the scalpel.

**Keywords:** diode laser, functional crown lengthening, scalpel, visual analog scale (vas)

## 1. Introduction

Numerous clinical situations such as subgingival caries, fractured teeth, worn out teeth, gummy smile etc. are encountered by dentists in day to day clinical practice. Interdisciplinary dentistry comes to play and specialists coordinate to salvage the teeth through a crown lengthening procedure to expose sufficient tooth structure to facilitate proper restoration as well as enhance esthetic appearance. Various indications have been outlined in literature for crown lengthening surgery, such as exposure of fractured tooth, correction of gummy smile, exposure of subgingival caries, access to subgingival root perforations etc. (Palomo, Rosenberg, & Bragger, 1978; Pradeep, Nagesh, Sood, Akula, & Rajani, 2013; Camargo, Melnick, & Camargo, 2007)

Based on the clinical scenario, crown lengthening procedure was categorized as either esthetic or functional. Young patients presenting with a gummy smile and short clinical crowns due to altered passive eruption requiring an increase in the length of the tooth structure were discussed under the “esthetic crown lengthening” category. Here, the crown lengthening procedure is confined to the anterior esthetic zone and helps in enhancing the esthetic appearance of an individual, whereas crown lengthening intended to expose subgingival caries or a fractured tooth relates to a “restorative/functional crown lengthening” (Hempton & Rosenberg, 2010). Some clinical situations warrant that both esthetic and functional crown lengthening surgery go hand in hand.

Crown lengthening procedures, either esthetic or functional have one common goal; not to violate the biologic

width. Preservation of biologic width is the therapeutic endpoint of both these procedures.

Numerous researchers have presented varied dimensions of the biologic width, but the dimensions put forward by Gargiulo (1961) and his fellow researchers stand tall. According to them, the length of the dentogingival junction was 2.04mm with two components; connective tissue attachment comprising of 1.07mm and the epithelial attachment comprising of 0.97mm (Gargiulo, 1961). Eventually, 3mm of tooth structure above the osseous crest is considered safe to prevent any attachment loss. (Ingber & Nevins, 1977)

Crown lengthening procedure is accomplished either by the use of a scalpel, electrocautery or more recently by the use of lasers (Allen, Wagenberg, Bashetty, McGuire, & Lagdive, 1993; Kalsi, Hussain, & Darbar, 2015). Owing to the advantages such as minimal discomfort and quick hemostasis and placement of restoration immediately, lasers have an added advantage over the scalpel in functional crown lengthening procedures but literature is scant to support the same (Pick, 1993).

Hence, our present clinical study was designed to assess the clinical effectiveness of a diode laser for functional crown lengthening procedure and to compare it with the conventional procedure using the scalpel.

## 2. Materials and Methods

Twenty two patients including males and females, aged 20-40 years were screened and recruited among thirty patients who were attending a private dental practice. Systemically healthy patients with adequate attached gingiva with the presence of subgingival caries, inadequate tooth structure were included in the study. Medically compromised patients, heavy smokers, pregnant and lactating patients and patients who previously underwent any surgical procedures in the same area were excluded from the study.

Crown lengthening procedure was properly explained to the patients and a signed consent was taken from them. Patients were divided into two groups through a computer generated randomization. Group A-comprising of eleven patients who underwent diode laser assisted crown lengthening procedure. Group B-comprising of eleven patients who underwent conventional scalpel surgical procedure. Prior to the crown lengthening procedure, patients received professional cleaning of their teeth and necessary oral hygiene instructions were given for proper maintenance of oral hygiene. Preoperative calibrating exercise was given to two operators (Operator A and Operator B) to standardize the protocol and to minimize the bias while recording the VAS scores.

### 2.1 Clinical Parameters

#### 2.1.1 VAS Scale for Scoring Patient Perceptions

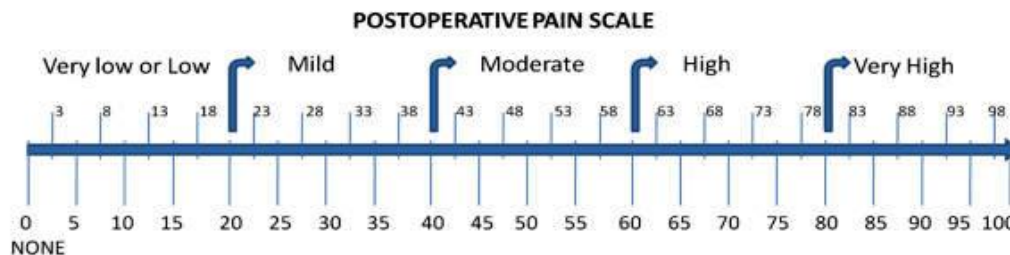


Figure 1. Patient perceptions related to pain and discomfort post operatively was assessed by a visual analog scale (VAS)

The VAS scale comprised of a 100mm scale with “0” indicated as “no” and 100 representing “plenty”. The two end points on the pain scale represented “no pain” on the left and “plenty of pain” on the right side. The discomfort scale was represented by “no discomfort” on the left and “plenty of discomfort” on the right. Patients were instructed to make a vertical mark between these two end points on the pain as well as the discomfort scale separately on the 3<sup>rd</sup>, 7<sup>th</sup> and the 10<sup>th</sup> days.

#### 2.1.2 Conventional Soft Tissue Crown Lengthening Procedure

The area around the teeth which were to undergo the procedure was sufficiently anesthetized with 2% lignocaine and 1:80,000 adrenalin. Initially the probing depth was measured and once sufficient anesthesia was achieved, biologic width calculation was done by the transgingival probing method using a William’s periodontal probe.

Once the biologic width was calculated and the amount of gingival tissue to be excised was demarcated to attain a proper exposure of the tooth structure, an external bevel incision was performed and the gingival tissue was

excised. Left out tissue tags and any beads of granulation tissue were removed to attain a smooth surface (Figures 2-4).

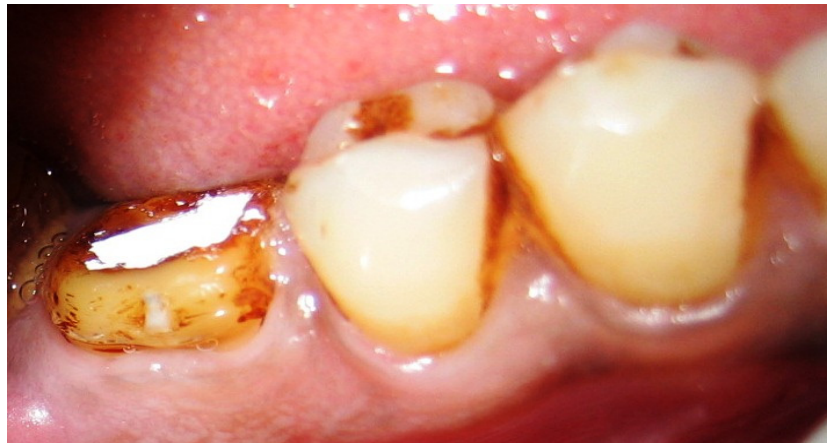

Figure 2. Preoperative photograph before crown lengthening in case 1

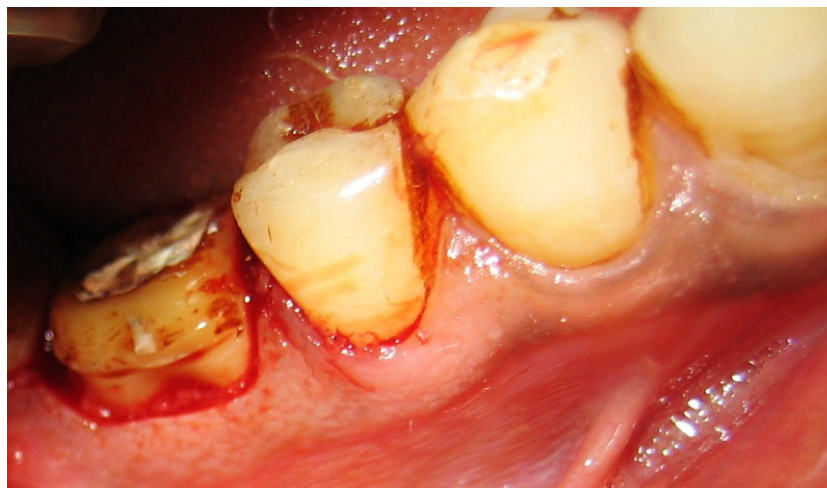


Figure 3. Photograph showing the crown lengthening with scalpel in case 1

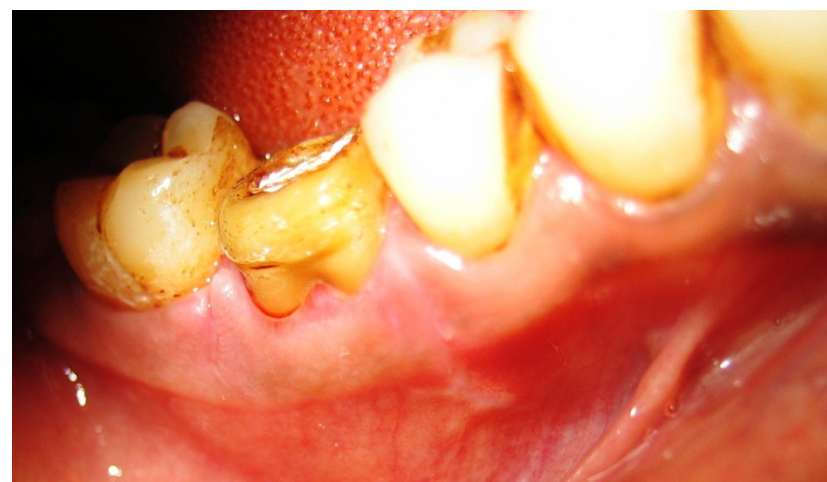

Figure 4. Post operative photograph after crown lengthening with scalpel in case 1

Patients were given all the post operative instructions and were prescribed analgesics. Adequate plaque control measures involving rinsing with 0.12% Chlorhexidine gluconate twice daily for about two weeks was advocated.

### 2.1.3 Laser Assisted Soft Tissue Crown Lengthening Procedure

Prior to the procedure, topical anesthetic gel was applied to the concerned area. Though a local anesthetic gel is sufficient considering that the procedure is minimally invasive, the area was adequately anesthetized with 2% lignocaine and 1:80,000 adrenaline. Safety precautions such as safety glasses for the concerned wavelength were put on by the clinician and the patient prior to the procedure.

A diode laser (Ezlase, Biolase Technologies; CA, USA) with a wavelength of 940nm was used for the procedure. After sufficient anesthesia was achieved, the laser unit comprising of a 400- $\mu$ m disposable tip was used in a contact mode with a setting of 0.8 to 1.5 watts in continuous mode along the demarcated area with a paint brush like strokes progressing slowly to remove the gingival tissue and expose adequate amount of tooth structure. During the entire procedure, the tip was constantly checked for any debris of the ablated tissues and was cleaned with sterile moist gauze. Physiological gingival contour was achieved by changing the angulation of the tip as required during the procedure (Figures 5-7).

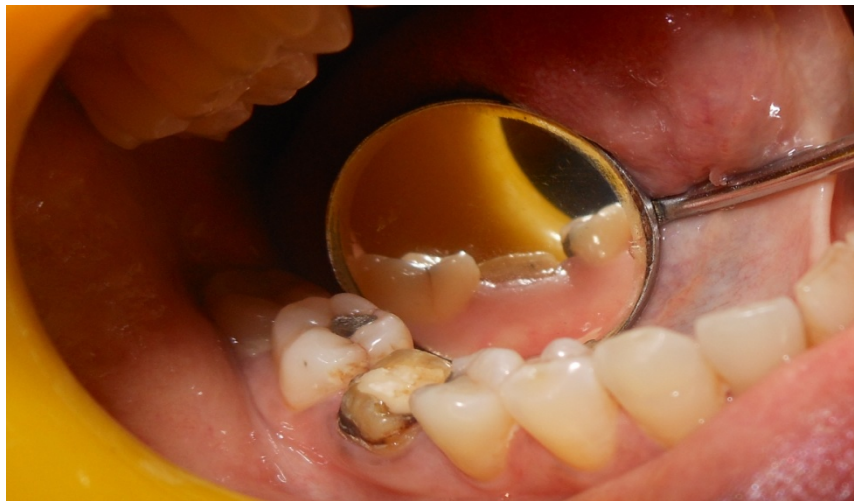

Figure 5. Preoperative photograph before crown lengthening in case 2

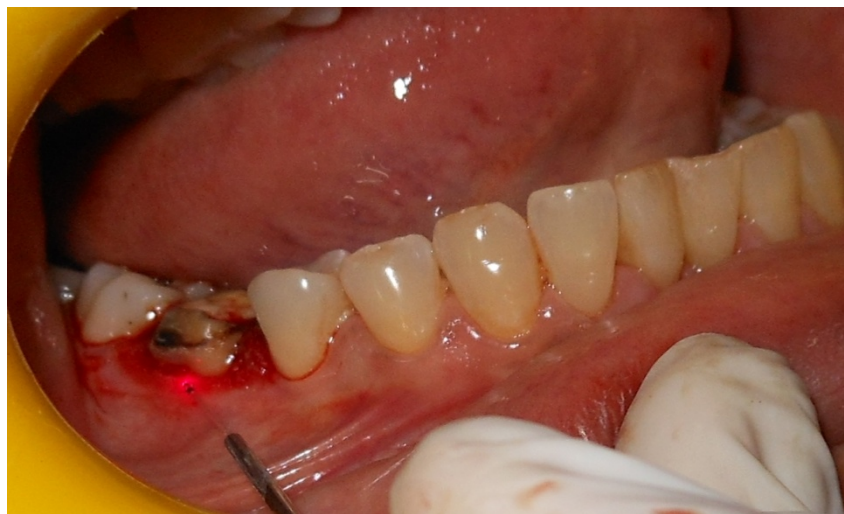

Figure 6. Photograph showing the crown lengthening with Laser in case 2

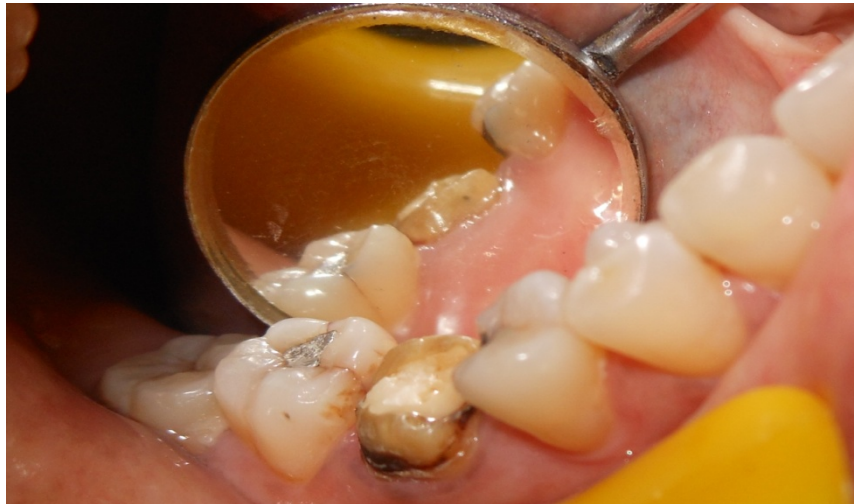

Figure 7. Post operative photograph after crown lengthening with Laser in case 2

Analgesics were prescribed for the patients and were advised to be taken if required. Out of 11 patients in scalpel group 8 patients reported the use of analgesics and 2 Patients reported use of analgesics in the laser group in the immediate 24 hour post operative period. Considering that the patients in both the groups having taken the analgesics only on the first postoperative day, this did not have an influence on the VAS scores as the patients were recalled on the 3<sup>rd</sup> day. Necessary plaque control measures and oral hygiene instructions were instructed to all the patients.

### 2.2 Statistical Analysis

An IBM Statistical Program for Social Sciences Version 17.0 (SPSS Inc, Chicago Illinois, USA) was used to perform statistical analysis. An Unpaired t-test was used to determine the statistical significance of data for all pain and discomfort scores between the groups and intragroup comparison was determined by ANOVA. Changes were considered significant at  $P < 0.05$  and highly significant at the  $P < 0.001$

### 3. Results

Fourteen patients had completed the follow up from a total of twenty two patients who had enrolled for the study. Patients were recalled on the 3<sup>rd</sup>, 7<sup>th</sup> and the 10<sup>th</sup> day for evaluation of VAS scores. Intragroup comparison of pain and discomfort VAS scores within the scalpel group is summarized in Table 1.

Table 1. Intragroup comparison of VAS scores of pain and discomfort in scalpel group (intragroup comparison)

| Scalpel group        | Pain      | Comparison                                      | P value | Discomfort | Comparison                                      | P value |
|----------------------|-----------|---|---------|------------|---|---------|
| 3 <sup>rd</sup> day  | 77.8±5.21 | 3 <sup>rd</sup> day versus 7 <sup>th</sup> day  | 0.03*   | 79.62±4.96 | 3 <sup>rd</sup> day versus 7 <sup>th</sup> day  | 0.04*   |
| 7 <sup>th</sup> day  | 27.8±0.79 | 7 <sup>th</sup> day versus 10 <sup>th</sup> day | 0.001*  | 35.30±3.32 | 7 <sup>th</sup> day versus 10 <sup>th</sup> day | 0.001*  |
| 10 <sup>th</sup> day | 2.1±3.51  | 3 <sup>rd</sup> day versus 10 <sup>th</sup> day | 0.001*  | 2.6±1.7    | 3 <sup>rd</sup> day versus 10 <sup>th</sup> day | 0.001*  |

Note. \* $P < 0.05$  significant

The VAS scores of pain and discomfort when compared from the 3<sup>rd</sup> day to the 7<sup>th</sup> day did show significant difference. However, when the scores from the 10<sup>th</sup> day were compared with those on the 3<sup>rd</sup> and the 7<sup>th</sup> days, a highly significant difference was found ( $P < 0.001$ ).

Intragroup analysis of VAS scores for pain and discomfort within the laser group are summarized in Table 2.

Table 2. Intragroup comparison of VAS scores of pain and discomfort in laser group (intragroup comparison)

| Laser group          | Pain     | Comparison                                      | P value | Discomfort | Comparison                                      | P value |
|----------------------|----------|---|---------|------------|---|---------|
| 3 <sup>rd</sup> day  | 67.5±7.7 | 3 <sup>rd</sup> day versus 7 <sup>th</sup> day  | 0.001*  | 50.5±6.0   | 3 <sup>rd</sup> day versus 7 <sup>th</sup> day  | 0.001*  |
| 7 <sup>th</sup> day  | 18.0±5.0 | 7 <sup>th</sup> day versus 10 <sup>th</sup> day | 0.001*  | 14.3±9.7   | 7 <sup>th</sup> day versus 10 <sup>th</sup> day | 0.001*  |
| 10 <sup>th</sup> day | 1.9±0.5  | 3 <sup>rd</sup> day versus 10 <sup>th</sup> day | 0.001*  | 2.3±1.7    | 3 <sup>rd</sup> day versus 10 <sup>th</sup> day | 0.001*  |

Note. \*P<0.001 significant

Within the laser group, The VAS scores of pain and discomfort when compared from the 3<sup>rd</sup> day to the 7<sup>th</sup> day did show significant difference. However, when the scores from the 10<sup>th</sup> day were compared with those on the 3<sup>rd</sup> and the 7<sup>th</sup> days, a highly significant difference was found (P<0.001).

Table 3 summarizes the intergroup comparison of the mean VAS scores of the levels of pain observed on the 3<sup>rd</sup>, 7<sup>th</sup> and the 10<sup>th</sup> day of the study. The results showed that there was a significant difference (P<0.002) in VAS scores of pain on the 3<sup>rd</sup> day as well as on the 7<sup>th</sup> day (P<0.044), with patients in the laser group displaying significantly lower VAS scores compared to the scalpel group, but when both the groups were compared on the 10<sup>th</sup> day, there was no significance (P<0.14).

Table 3. Intergroup comparison of VAS scores of pain (between groups comparison)

|                      | Scalpel   | Laser    | P value |
|----------------------|-----------|----------|---------|
| 3 <sup>rd</sup> day  | 77.8±5.21 | 67.5±7.7 | 0.002*  |
| 7 <sup>th</sup> day  | 27.8±0.79 | 18.0±5.0 | 0.044*  |
| 10 <sup>th</sup> day | 2.1±3.51  | 1.9±0.5  | 0.14#   |

Note. \*P<0.05 Statistically Significant, # P>0.05 Statistically Not Significant

Table 4 represents the intergroup comparison of the mean VAS scores for discomfort observed on the 3<sup>rd</sup>, 7<sup>th</sup> and the 10<sup>th</sup> day of the study. Analysis of the results suggested that there was a significant difference of the VAS scores of discomfort on the 3<sup>rd</sup> and the 7<sup>th</sup> days, with the patients in the laser group displaying significantly lower VAS scores for discomfort, but again the intergroup comparison for VAS scores for discomfort were not significant on the 10<sup>th</sup> day (P<0.13).

Table 4. Intergroup comparison of VAS scores discomfort (between groups comparison)

|                      | Scalpel    | Laser    | P value |
|----------------------|------------|----------|---------|
| 3 <sup>rd</sup> day  | 79.62±4.96 | 50.5±6.0 | 0.002*  |
| 7 <sup>th</sup> day  | 35.30±3.32 | 14.3±9.7 | 0.005*  |
| 10 <sup>th</sup> day | 2.6±1.7    | 2.3±1.7  | 0.13#   |

Note. \*P<0.05 Statistically Significant, # P>0.05 Statistically Not Significant

#### 4. Discussion

Various lasers such as Nd: YAG, Er, Cr: YSGG, Er: YAG and diodes have been used for crown lengthening (Barr, Yung, Hoopingarner, & Olivi, 2001; Verma, Maheshwari, Singh, & Chaudhari, 2012). Most of these were either case reports or case series. Our present clinical study was to evaluate patient perceptions and assess the effectiveness of a diode laser compared with the conventional technique for a functional/restorative soft tissue crown lengthening.

Functional crown lengthening procedure involves either a gingivectomy or an open flap surgical technique with resective osseous surgery to attain the biologic width conducive for restoration and crown placement. Matter of choice between gingivectomy and an open flap surgical technique depends upon several factors, one of which is the width of attached gingiva (Hempton, 2010). Our study included only those patients who had a sufficient width of attached gingiva requiring a simple gingivectomy procedure either with the laser or the scalpel.

Comparing both the laser and the scalpel techniques, indeed both the techniques resulted in sufficient removal of the gingival tissue with adequate exposure of the tooth structure. Patients in the laser group had minimal bleeding which permitted better visualization of the operative area and better assessment of the necessary tooth structure to be exposed whereas the scalpel wound resulted in unpleasant bleeding with poor visualization of the operative area. Our findings were in accordance with Lagdive SB et al. (2010).

A VAS scale was used to assess the patient perceptions for pain and discomfort between both the groups. Patients in the laser group exhibited a reduction in the VAS scores on the 3<sup>rd</sup> day and the 7<sup>th</sup> day compared to the scalpel group primarily because lasers deposit a protein coagulum sealing the sensory nerves leading to a reduction in inflammation (Hoopingarner, 2008).

Various lasers with specific wavelengths were used for soft tissue and hard tissue crown lengthening procedures. We preferred a diode laser considering them to be compact and cost effective and owing to the fact that these lasers have a better penetration depth with better absorption for melanin and hemoglobin with relatively better hemostasis compared to other lasers. Other advantages of the laser over scalpel include a reduced edema due to the sealing of lymphatic vessels and less wound contraction as well as scarring (Vescovi et al., 2010).

## 5. Conclusion

Laser has indeed shown some advantages such as better hemostasis, less inflammation and a sterile wound cut compared with the scalpel in soft tissue restorative crown lengthening. Though there are certain disadvantages such as tissue necrosis and lateral heat damage with the use of laser; within the limitations of this present clinical study the diode laser can champion the cause as an alternative to scalpel for an effortless and minimally invasive soft tissue restorative crown lengthening procedure.

## References

- Allen, E. P. (1993). Surgical crown lengthening for function and esthetics. *Dent Clin North Am*, 37, 163-179.
- Barr, R. E. (2001). Nd: YAG laser gingival crown lengthening and tissue retraction for impressions. *Wavelengths*, 9(2), 17.
- Bashetty, K., Nadig, G., & Kapoor, S. (2009). Electrosurgery in aesthetic and restorative dentistry: A literature review and case reports. *J Conserv Dent*, 12, 139-144. <http://dx.doi.org/10.4103/0972-0707.58332>
- Bragger, U., Lauchenauer, D., & Lang, N. P. (1992). Surgical lengthening of the clinical crown. *J Clin Periodontol*, 19, 58-63. <http://dx.doi.org/10.1111/j.1600-051X.1992.tb01150.x>
- Camargo, P. M., Melnick, P. R., Camargo, L. M. (2007). Clinical Crown Lengthening in Esthetic Zone. *J Calif Dent Assoc*, 35(7), 487-98.
- Gargiulo, A., Wentz, F., & Orban, B. (1961). Dimensions and relations of the dentogingival junction in humans. *J Periodontol*, 32, 261-267. <http://dx.doi.org/10.1902/jop.1961.32.3.261>
- Hempton, T. J., & Dominici, J. T. (2010). Contemporary Crown-Lengthening Therapy: A review. *JADA*, 141(6), 647-655. <http://dx.doi.org/10.14219/jada.archive.2010.0252>
- Hoopingarner, C. R. (2008). Soft tissue gingivoplasty, osseous recontouring/crown lengthening, and frenectomy using an Er: YAG laser. *J Laser Dent*, 16(2), 81-86.
- Ingber, J. S., Rose, L. F., & Coslet, J. G. (1977). The "biologic width": A concept in periodontics and restorative dentistry. *Alpha Omegan*, 70(3), 62-65.
- Kalsi, H. J., Bomfim, D. I., & Darbar, U. (2015). An Update on Crown Lengthening. Part 2: Increasing Clinical Crown Height to Facilitate Predictable Restorations. *Dent Update*, 42(3), 230-2, 235-6.
- Kalsi, H. J., Hussain, Z., & Darbar, U. (2015). An update on crown lengthening. Part 1: Gingival tissue excess. *Dent Update*, 42(2), 144-6, 149-50, 153.
- Lagdive, S. B., Lagdive, S. S., Marawar, P. P., Bhandari, A. J., Darekar, A., & Saraf, V. (2010). Surgical lengthening of the clinical tooth crown by using semiconductor diode laser: A case series. *J Oral Laser Applications*, 10, 53-57.
- McGuire, M. K., & Scheyer, E. T. (2011). Laser-assisted flapless crown lengthening: A case series. *Int J Periodontics Restorative Dent*, 31(4), 357-364.
- Nevins, M., & Skurow, H. M. (1984). The intracrevicular restorative margin, the biologic width, and the maintenance of the gingival margin. *Int J Periodontics Restorative Dent*, 4(3), 31-49.

- Olivi, G. (2006). Hard and soft tissue Er, Cr: YSGG laser application: Multiple closed flap crown lengthening in esthetic anterior area. *J Acad Laser Dent, 14*(2), 21-25.
- Palomo, F., & Kopczyk, R. A. (1978). Rationale and methods for crown lengthening. *J Am Dent Assoc, 96*(2), 257-260. <http://dx.doi.org/10.14219/jada.archive.1978.0066>
- Pick, R. M. (1993). Using lasers in clinical dental practice. *J Am Dent Assoc, 124*(2), 37-44. <http://dx.doi.org/10.14219/jada.archive.1993.0027>
- Pradeep, K., Patil, N., Sood, T., Akula, U., & Rajani, G. (2013). *J Clin Diagn Res, 7*(10), 2387-2389.
- Rosenberg, E. S., Cho, S. C., & Garber, D. A. (1990). Crown lengthening revisited. *Compend Contin Educ Dent, 20*(6), 527-542.
- Rosenberg, E. S., Garber, D. A., & Evian, C. I. (1980). Tooth lengthening procedures. *Compend Contin Educ Dent, 1*, 161-172.
- Verma, S. K., Maheshwari, S., Singh, R. K., & Chaudhari, P. K. (2012). Laser in dentistry: An innovative tool in modern dental practice. *Natl J Maxillofac Surg, 3*(2), 124-132. <http://dx.doi.org/10.4103/0975-5950.111342>
- Vescovi, P., Corcione, L., Meleti, M., Merigo, E., Fornaini, C., Manfredi, M., ... Nammour, S. (2010). Nd: YAG laser versus traditional scalpel. A preliminary histological analysis of specimens from the human oral mucosa. *Lasers Med Sci, 25*, 685-691. <http://dx.doi.org/10.1007/s10103-010-0770-4>
- Wagenberg, B. D., & Eskow, R. N. L. (1989). Exposing adequate tooth structure for restorative dentistry. *Int J Periodontics Restorative Dent, 9*, 323-331.
- Yung, F. (2003). 980-nm diode laser vital pulp capping and soft tissue crown lengthening. *Wavelengths, 11*(2), 16-18.

### Copyrights

Copyright for this article is retained by the author(s), with first publication rights granted to the journal.

This is an open-access article distributed under the terms and conditions of the Creative Commons Attribution license (<http://creativecommons.org/licenses/by/3.0/>).