



# Thoracodorsal Artery Perforator Flap for Chronic Radiation-Induced Ulcer Grade 4: A Case Series Report

Kristanto Yuli Yarso<sup>1\*</sup> and Monica Bellinda<sup>2</sup>

<sup>1</sup>Oncology Division, Surgery Department, Sebelas Maret University, Surakarta, Indonesia.

<sup>2</sup>Surgery Department, Sebelas Maret University, Surakarta, Indonesia.

## Authors' contributions

*This work was carried out in collaboration between both authors. Both authors read and approved the final manuscript.*

## Article Information

### Editor(s):

(1) Dr. Arun Singh, Rohilkhand Medical College & Hospital Bareilly, India.

### Reviewers:

(1) Diego Renatto Chambergo Michilot, Universidad Científica del Sur, Perú.

(2) Giovanna R. Degasperi, Pontifical Catholic University of Campinas, Brazil.

Complete Peer review History: <http://www.sdiarticle4.com/review-history/64921>

**Received 22 November 2020**

**Accepted 29 January 2021**

**Published 25 February 2021**

Case Study

## ABSTRACT

**Background:** Radiotherapy takes an important role in the management of breast cancer. Therefore, radiation-induced skin ulcer caused by the acute or chronic effects of ionizing radiation might be another challenge. The treatment of chronic radiation-induced ulcers is further complicated because they are often combined with other radiation side effects.

**Case Presentation:** We report two cases of women suffering from breast cancer. These patients had mastectomy surgery 7 and 10 years ago followed with 70 Gy external beam radiation therapy using cobalt 60. The first patient had a chronic expanded ulcer in the last 2 years with a diameter of 10 x 4 cm now. In the second patient, the ulcers formed as a hole under the armpit in the past 1 year with a size of 3 x 2 cm. Both patients' ulcers were odorless, pale in color on surrounding tissue with no sign of granulation and no pus. After a long period of treatment with no results, we decided to use a thin layer flap rich in vascularization for both cases. The flap chosen was the thoracodorsal artery perforator flap. From both cases, follow-up postoperative showed good results in coverage, cosmetic, and functional aspects. The flap perforator succeeds

\*Corresponding author: E-mail: [yarsaonko@gmail.com](mailto:yarsaonko@gmail.com);

in creating less bulky coverage, free range of motion, no infection, flap loss, and necrosis at the site.

**Conclusion:** Thoracodorsal artery perforator flap is a safe option for the reconstruction of skin ulcer caused by radiation. This technique has the advantage of reducing donor site morbidities.

*Keywords: Radiation-induced ulcer; thoracodorsal artery perforator; perforator flap.*

## 1. INTRODUCTION

Breast cancer is the most frequent cancer in woman. The incidence of cancer-related deaths is dominated by breast cancer. In 2020, 685,000 women died from breast cancer [1].

There are several therapeutic approaches for breast cancer cure. Radiotherapy takes an important role in the management of breast cancer. Radiation leads to less extensive surgeries while maintaining relapse-free and overall survival [2]. Still, every approach has side effects. Radiation ulcers are wounds caused by the acute or chronic effects of ionizing radiation. The injury may involve the skin, underlying soft tissue, and even deep structures such as bone. Radiation-induced lesions may appear up to 10 years after irradiation and are initiated by damage to the vascular endothelial microvessels [3]. This damage eventually causes non-healing ulcers and soft tissue necrosis. The treatment of chronic radiation-induced ulcers in the chest wall (CRUCW) is further complicated because they are often combined with radiation osteomyelitis, radiation pneumonitis, brachial plexus injury, and other comorbidities [4-5].

Perforator flaps are an important step in the evolution of reconstructive surgery. Deepithelialized flaps from the lateral thoracic wall and the back can be transposed to the anterior thorax for breast mound reconstruction using the thoracodorsal artery perforator (TDAP) flap [6]. TDAP flap represents a multipurpose muscle-sparing flap that has reliable cutaneous blood supply originating from the lateral branch of the thoracodorsal artery [7]. The anatomical distribution of TDAP taking origins from the subscapular trunk. The thoracodorsal vessels course towards the latissimus dorsi continues to the serratus anterior branch and then divides into the transverse branch (medial) and the vertical branch (lateral). The lateral branch courses vertically and at least 2–3 cm inside the lateral border of the latissimus dorsi. A perforator or combinations of perforators off the distal main thoracodorsal artery or its vertical branch

constitute the vascular supply of the TDAP flap [8].

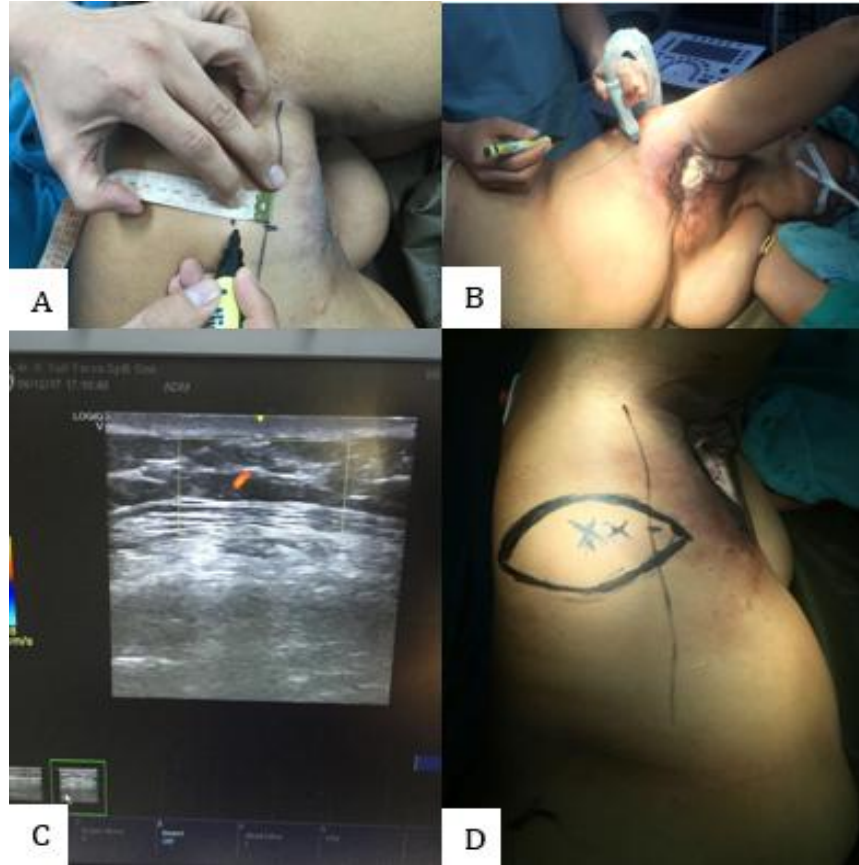
## 2. CASE PRESENTATION

We report two cases of women suffering from breast cancer. These patients had mastectomy surgery 7 and 10 years ago and continued with 70 gy of external beam radiation therapy. Both patients had cancer subtype Luminal A and received Paclitaxel and Epirubicin chemotherapy. Both of them got external beam radiation from cobalt 60 source.

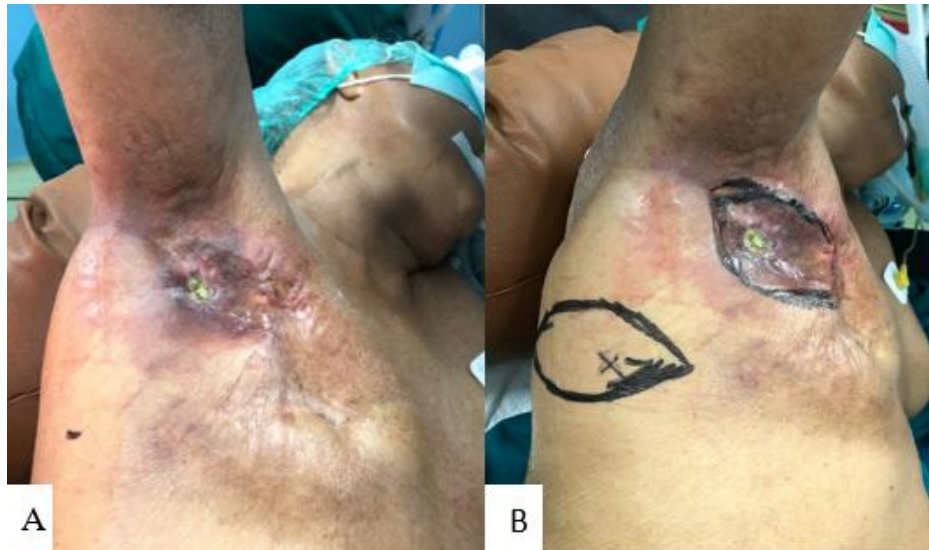In the first patient, the ulcers have been appeared in the last few years and expanded to form an ulcer with a size of 10 x 4 cm in an elliptical shape (Fig. 1). It has been treated in a rural hospital for a year, but it has not improved. The ulcer is odorless and has no pus. At the time of the biopsy, the pathological result was chronic inflammation and no malignancy. The surrounding skin was dark, stiff, and attached to the thoracic wall. Some minor pectoral muscles are still viable.

For the second patient, the ulcers formed as a hole under the armpit with a size of 3 x 2cm (Fig. 2). The ulcer is odorless and dark with the flat surrounding skin and no pus. After a one-year treatment with no results at the rural, hospital this patient was referred to our hospital.

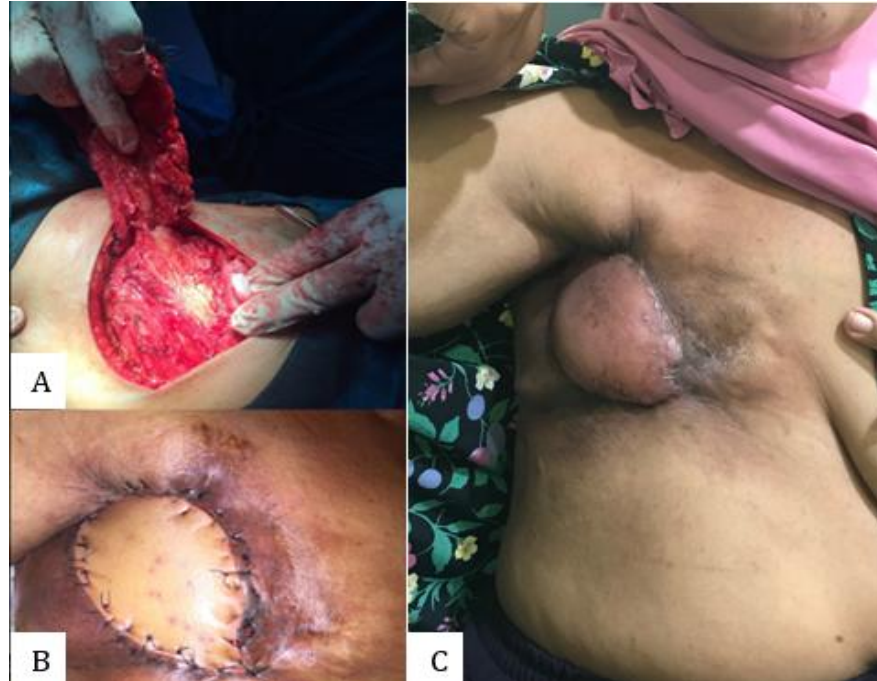We decided to use a flap perforator for both cases. We planned a flap reconstruction technique for these cases. We need a thin and good vascularized flap to cover this wound. The thoracodorsal artery perforator flap was chosen due to the ulceration that lies laterally near the axilla. From both cases, monthly follow-up postoperative showed good results in coverage, cosmetic, and functional aspects (Figs. 3, 4). The flap perforator succeeds creating less bulky coverage despite some minor scarring issues. For the functional aspect, the patient did not experience a range of motion limitations of the surrounding flap area.



**Fig. 1. Preoperative condition of the first case**  
A: Site mark, B and C: Doppler ultrasound, D: Site mark

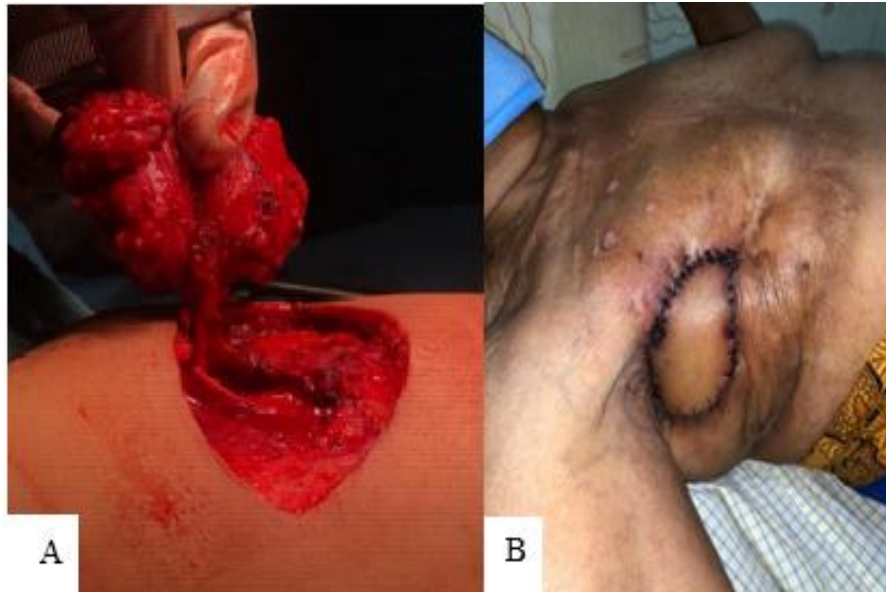

**Fig. 2. Preoperative condition of the second case**  
A: ulcer condition, B: donor site mark



**Fig. 3. The result of the first case**

*A: Durante op, B: Post-operative result C: A month post-operative follow-up*



**Fig. 4. The result of the second case**

*A: Durante op, B: A month post-operative result*

### 3. DISCUSSION

A flap is needed for deep ulceration, mainly those which penetrate the skin to tissue. The musculoskeletal flap provides better blood supply

than the cutaneous flap, but it usually causes a bulk closure [8]. A perforator flap could overcome the bulk closure formation. A thin flap with an adequate vascular supply ensures a good outcome for the patient. Thoracodorsal Artery

Perforator flap is one of the most commonly used as a perforator flap [9]. This technique superiority is in that the donor location is far from the radiation area and the easy access to mobilizing the flap to the ulceration site. The flexibility that comes from the long pedicle could locate the flap on the ulceration site, preventing a bulky coverage. To determine the viability of the perforator that will be used for donors at our institution, we usually use US Doppler to determine the pulsation and vitality of blood vessels. Doppler mapping for every TDAP should be considered as a routine preoperative procedure for its accuracy in detecting those vessels correctly [10]. The patient should be placed in a proper position during the surgery which allows access to the pedicle origin and direct transfer of the flap to the site. Contralateral decubitus position with the assistance holds the patient's arm believed as the proper setting.

For both cases in this study, there was no donor site morbidities. There were no infections, flap loss, necrosis at the site, and seroma build-up. This finding is parallel with other studies that also reported zero percent seromas after using this TDAP technique [11-13]. The lack of dead space resulting from muscle conservation was probably the main reason for the absence of seroma formation. With the absence of seroma, the risk of the infected site far decreased. This is a major advantage of the TDAP technique [10].

#### 4. CONCLUSIONS

Our report shows that thoracodorsal artery perforator flap is a safe option for the reconstruction of skin ulcer caused by radiation. Therefore we suggest future studies with a longer follow-up time to ensure safety. This technique has the advantage of reducing donor site morbidities mainly from infection due to the prior condition of exposed ulcers. This technique also provides a long flexible pedicle which reduces the risk of bulky coverage formation.

#### CONSENT

As per international standard, parental written consent has been collected and preserved by the authors.

#### ETHICAL APPROVAL

This study was approved by the Health Research Ethics Committee Faculty of Medicine Sebelas Maret University.

#### COMPETING INTERESTS

Authors have declared that no competing interests exist.

#### REFERENCES

1. WHO. Cancer Today – Estimated number of deaths worldwide, females, all ages; 2020. Available: <https://gco.iarc.fr/today/online-analysis-multi-bars?v=2020>
2. Ahmed KA, Grass GD, Orman AG, Liveringhouse C, Montejo ME, Soliman HH, et al. Personalizing radiation treatment delivery in the management of breast cancer. *Int J Breast Cancer*. 2018;6729802.
3. Schindl A, Schindl M, Schindl L. Phototherapy with low intensity laser irradiation for a chronic radiation ulcer in a patient with lupus erythematosus and diabetes mellitus. *Br J Dermatol*. 1997; 137:840–841.
4. Ferreira PC, Malheiro EL, Pereira JM, Rodrigues JM, Amarante JM. Neglected chest wall radiation-induced ulcers. *Breast J*. 2005;11:215–216.
5. Johansson S. Radiation induced brachial plexopathies. *Acta Oncol*. 2006;45:253–257.
6. Angrigiani C, Rancati A, Escudero E, Artero G, Gercovich G, Deza EG. Propeller thoracodorsal artery perforator flap for breast reconstruction. *Gland Surg*. 2014; 3(3):174–80.
7. Yang JD, Kim MC, Lee JW, Cho YK, Choi KY, Chung HY, et al. Usefulness of oncoplastic volume replacement techniques after breast conserving surgery in small to moderate-sized breasts. *Arch Plast Surg*. 2012;39:489-96.
8. Stanford Health Care. Flap surgery. Available: <https://stanfordhealthcare.org/medical-treatments/p/plastic-surgery/procedures/flap.html>
9. Sever C, Uygur F, Kulahci Y, Karagoz H, Sahin C. Thoracodorsal artery perforator fasciocutaneous flap: A versatile alternative for coverage of various soft tissue defects. *Indian J Plast Surg*. 2012; 45(3):478 .
10. Amin AA, Rifaat M, Farahat A, Hashem T. The role of thoracodorsal artery perforator

- flap in oncoplastic breast surgery. J Egypt Natl Canc Inst. 2017;83–87.
11. Thomsen JB, Rindom MB, Rancati A, Angrigiani C. Thoracodorsal artery flaps for breast reconstruction—the variants and its approach. Archives of Plastic Surgery. 2021;48(1):15.
  12. Angrigiani C, Rancati A, Escudero E, and Artero G. Extended thoracodorsal artery perforator flap for breast reconstruction. Gland Surg. 2015;1-9
  13. Hamdi M, Landuyt KV, Hijjawi JB, Roche N, Blondeel P, and Monstrey S. Surgical technique in pedicled thoracodorsal artery perforator flaps: a clinical experience with 99 patients. Plast Reconstr Surg. 2008;121(5):1632–41.

© 2021 Yarso and Bellinda; This is an Open Access article distributed under the terms of the Creative Commons Attribution License (<http://creativecommons.org/licenses/by/4.0>), which permits unrestricted use, distribution, and reproduction in any medium, provided the original work is properly cited.

*Peer-review history:*

*The peer review history for this paper can be accessed here:  
<http://www.sdiarticle4.com/review-history/64921>*