

Endoscopic and Intraoral Approach for Removal of an Ectopic Third Molar associated with a Dentigerous Cyst in the Maxillary Sinus: A Case Report

KANI BILGINAYLAR¹, HASAN METE INANCI², MELIZ KNEEBONE³

ABSTRACT

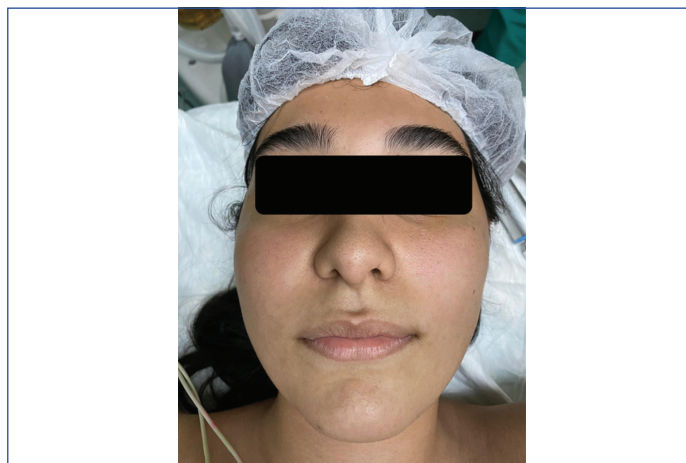Dental ectopia is the presence of deciduous, permanent, or supernumerary teeth in non dentate areas. It is very rare, especially in the maxillary sinus. Treatment is surgical removal because left untreated, there is a tendency to form a cyst, tumour, or lesion that can cause the perforation of the orbital floor and the obstruction of the nasal cavity. Although, panoramic radiography is the common form of radiological examination for this type of eruption, Cone Beam Computed Tomography (CBCT) is the gold standard for pinpointing the exact location of the ectopic tooth and evaluating the characteristics of any associated lesion prior to a surgical procedure. A 17-year-old woman was referred with swelling, asymmetry, and local pain in her right maxillary region. On radiological examination, an ectopic third molar surrounded by a dentigerous cyst obstructing both the right maxillary and ethmoid sinuses was observed. The tooth was attached to the zygomatic bone, right under the orbital floor. Ectopic maxillary third molars are extracted mainly by the Caldwell-Luc technique but also by nasal endoscopy. The treatment of this eruption and its management is heterogeneous and multidisciplinary. In the present case, under general anaesthesia, the ectopic tooth and all cystic tissue occupying the entire right maxillary and ethmoid sinuses were successfully enucleated with an intranasal endoscopic approach by an otolaryngologist and with lateral sinus antrostomy, utilising a standard Caldwell-Luc approach, by an oral and maxillofacial surgeon. After the 6th and 12th months, the patient had no signs of sinus infection and had an uneventful recovery.

Keywords: Caldwell-Luc technique, Computed tomography, Dental ectopia, Endoscopic surgery

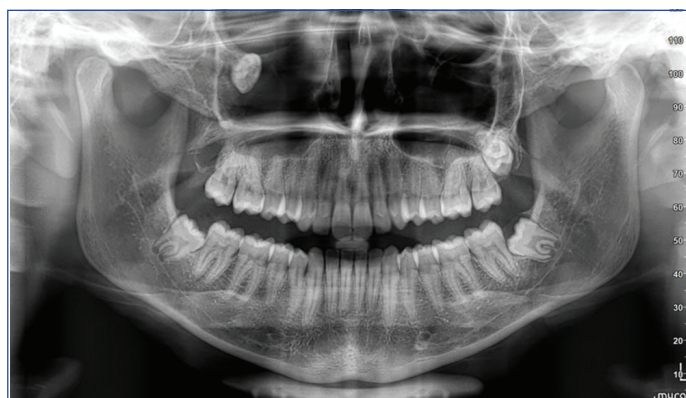CASE REPORT

A 17-year-old woman was referred to the Department of Maxillofacial Surgery at Final International University with a history of swelling and pain in the right maxillary sinus region since one month. The chief complaint was spontaneous pain which was awakening her from sleep. She then gave a history of blunt pain in the apex region of the teeth, especially when pressure was applied, asymmetry due to swelling, and inability to breathe from the right nasal cavity. The patient had undergone tonsillectomy at the age of six, and she had no other medical history, systemic disease, dental history, or trauma. The extraoral examination of the patient, also revealed the presence of diffuse, soft, and tender swelling on the anterior wall of the right maxillary sinus, causing facial asymmetry [Table/Fig-1]. Moreover, mild tenderness and pain were present while palpating the right cheek. Additionally, there was a complaint of difficulty in breathing due to the obstruction of the nasal airway in the right nostrils. The intraoral examination of the patient revealed that, all permanent teeth upto the second molars were present, and there were no dental problems such as caries or fractures in the teeth, or abscess or fistula formation in the gingiva. However, when palpating the apical areas of the right maxillary posterior teeth, pain and diffuse swelling were detected.

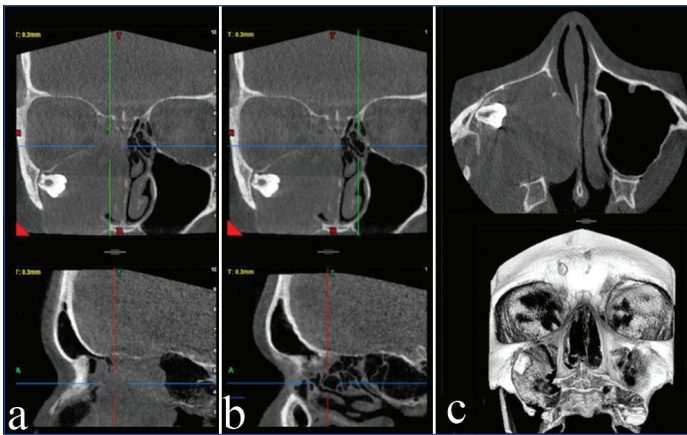
After a panoramic examination [Table/Fig-2], an ectopic third molar was detected in the maxillary sinus and a CBCT scan was ordered for the patient. According to the CBCT scan result, the patient's entire right maxillary and ethmoid sinuses demonstrated an opacity that indicated the presence of a cystic lesion [Table/Fig-3a]. On the contrary, at the left ethmoid and maxillary sinuses, there were no pathological findings [Table/Fig-3b]. There was no pathological sign in the sphenoid and frontal sinuses. The tooth was located in the right maxillary roof, attached to the zygomatic bone, just under the orbital floor [Table/Fig-3a-c]. After the first examination, the



[Table/Fig-1]: Preoperative view of the patient showing facial asymmetry on the right side.



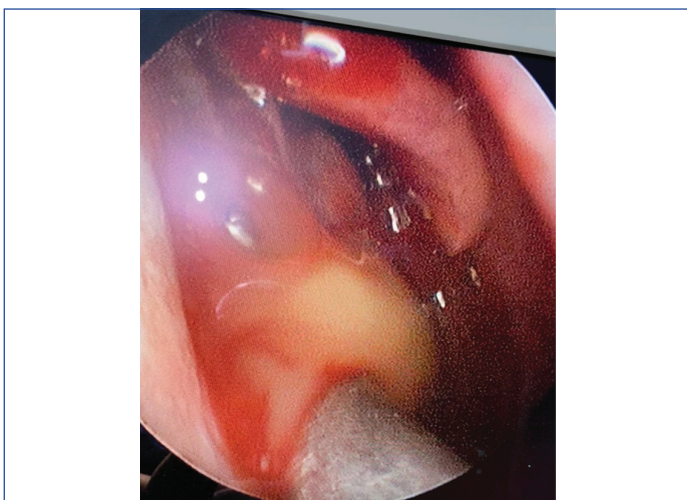
[Table/Fig-2]: Panoramic examination of the patient showing ectopic third molar on right maxillary sinus.



[Table/Fig-3]: a) Coronal and sagittal plane of CBCT showing radiopacity in the right side of patient; b) Coronal and sagittal plane of CBCT showing no pathologic findings in the left side of patient; c) Axial plane and 3D view of ectopic tooth.

odontogenic cyst with an ectopic maxillary third molar was made as a provisional diagnosis. The differential diagnosis of the lesion was maxillary sinusitis, an infected dentigerous cyst, or an odontogenic keratocyst. After dental examination, the patient was referred to an otolaryngologist for further examination including intranasal examination with a speculum and headlamp. Her nasal examination revealed that, the right turbinates were more expansive, and they obstructed the airway. Clinical and tomographic evaluations proved that, there was a massive lesion inside the maxillary and ethmoid sinuses, and a nasal approach was required. For the treatment, enucleation and curettage were planned. Therefore, the patient was informed that, the lesion and ectopic tooth should be removed endoscopically from the nose and intraorally with the Caldwell-Luc method under general anaesthesia.

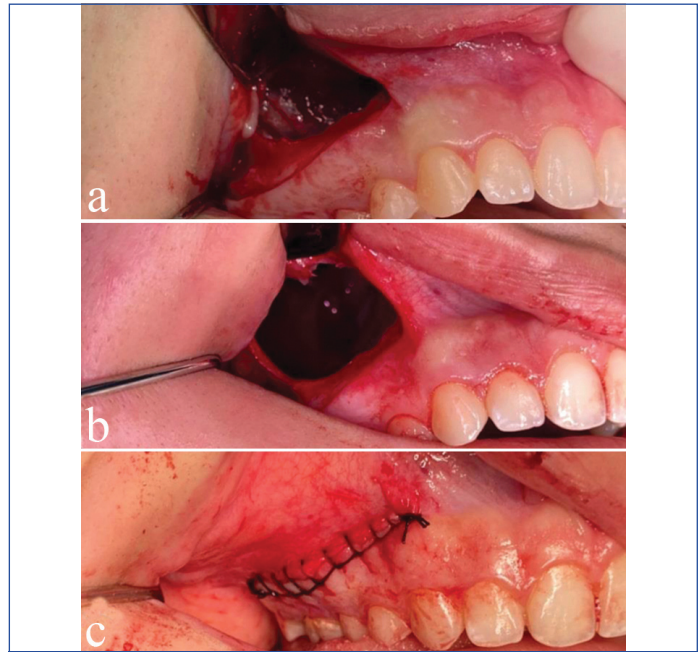
First, the patient was intubated orally, the surgery then started with an endoscopic sinus approach by entering from the right nasal cavity of the patient, and a mass lesion that filled the middle meatus, medialised the middle turbinate, and abutted on the septum was seen. Following the mucosal injection of jetokain, the medial wall of the maxillary sinus was excised by uncinectomy. The cyst fluid in the ethmoid and maxillary sinus was drained the cyst epithelium was excised, as much as, possible using the nasal endoscopic approach [Table/Fig-4] and the nasal packing was placed to be removed one day later. It was observed that, the mass lesion was fixed to the maxillary mucosa, and it was decided to excise it through the window to be opened from the anterior wall of the maxillary sinus with the Caldwell-Luc method.



[Table/Fig-4]: The view of cyst fluid after the intranasal incision.

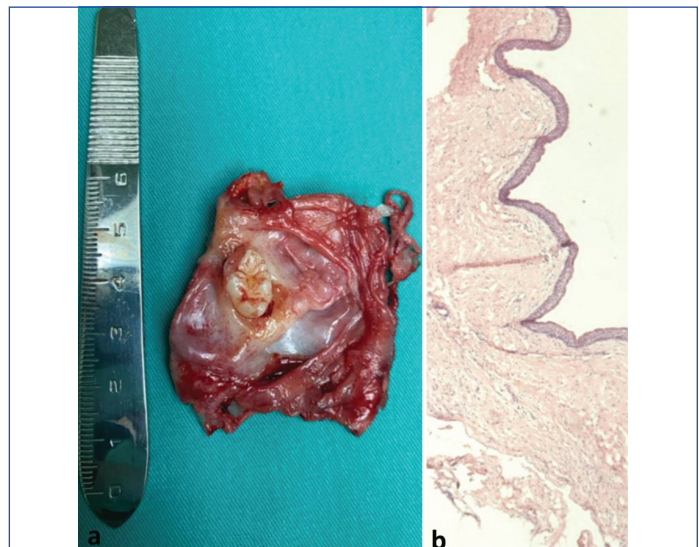
The incision was made from the mesial to the distal direction using the number 15 scalpel blade, following the attached gingival border between the right upper canine and the second molar. After full-thickness mucoperiosteal flap reflection, the anterior wall of the

maxillary sinus was resorbed. Thus, the cyst epithelium was directly exposed [Table/Fig-5a]. After the enucleation of the cyst with the ectopic tooth, the sinus cavity was cleaned with sterile normal saline solution containing no antibacterial agents [Table/Fig-5b], haemostasis was achieved, the wound was closed with 3.0 silk sutures, and primary closure was performed with the continuous locked suture technique [Table/Fig-5c]. The patient was instructed to take amoxicillin/clavulanate potassium (875/125 mg) 2 times/day and metronidazole (500 mg) three times/day for five days, as well as, using antiseptic (povidone-iodine 7.5%) mouthwash three times/day for seven days. Flurbiprofen (100 mg) was also prescribed postoperatively, to be taken as required. The suture was removed on the 7th postoperative day. After recovery from surgery, the patient was able to breathe well through the right side of the nose, and all her other preoperative symptoms, including pain, pressure, and swelling, resolved.

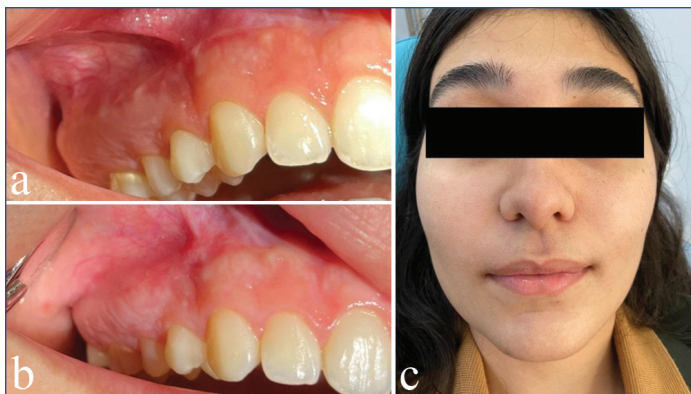

[Table/Fig-5]: a) Intraoral view of incision and mucoperiosteal flap reflection; b) The view of sinus cavity after the enucleation of cystic content and ectopic tooth; c) The view of primary closure with continues locked suture.

After the surgery, the lesion was sent to a histopathologist for diagnosis. The gross picture of ectopic tooth and dentigerous cyst along with the histopathological examination of the soft tissue, which revealed a non keratinised stratified squamous epithelium which was compatible with a dentigerous cyst [Table/Fig-6a,b].



[Table/Fig-6]: a) The view of ectopic tooth and dentigerous cyst after surgery; b) Histopathologic findings of non keratinised stratified squamous epithelium (haematoxylin and eosin, x200).



[Table/Fig-7]: The view of intraoral region of operated area at the 6th month, 1st year and extraoral photo at the 1st year follow-up, respectively.

As a result of the clinical and radiological examinations, performed at the end of six months and at one year follow-up, no signs of maxillary infection were found, and the airways were completely opened. Hence, there was no need for reoperation during this period [Table/Fig-7a-c].

DISCUSSION

Dental ectopia is the presence of deciduous, permanent, or supernumerary teeth outside the dental arch [1]. The aetiology of ectopic eruption is considered to include trauma, infection, and abnormal tissue interactions during dental development. However, in many cases, the aetiology may be idiopathic or because of developmental disorders such as cleft palate, trauma, genetic factors, and high bone density. The location of ectopic teeth can be in the mandibular condyle, coronoid process, nasal cavity, palate, or maxillary sinus. Furthermore, the most common ectopic eruption is seen in wisdom teeth [2,3]. Approximately 70% of dentigerous cysts form in the mandible, and 30% are in the maxilla [2,4]. The ectopic eruption of maxillary third molars is rare [1-4]. Moreover, dentigerous cysts associated with ectopic teeth in the maxillary sinus were reported in 87% of 39 cases which were searched on PubMed in studies published until 2021 without a time limit [5]. Among all 39 teeth, 22 teeth were 18 while, 17 were 28 [5]. According to Coutrot et al., the sex ratio was reported as 2:3 (13 females and 20 males). Additionally, 79% of the ectopic maxillary third molar cases were clinically symptomatic. The three most frequent symptoms were swelling (57%), chronic infection manifesting as a purulent posterior or anterior nasal discharge (53%), and local pain (51%), followed by headache (18%) and a sensation of a feeling of heaviness in the sinus (15%). Three of these symptoms were found in half of the patients, and they led to significant morbidity. These three symptoms were local pain, swelling, and anterior or posterior nasal discharge. This triad is characteristic of chronic infection of the ectopic third molar and/or the associated cyst [5]. Additionally, general anaesthesia was induced in 36% of patients, and local anaesthesia was used in 28%. 1 (3%) patient had surgery under neuroleptanalgesia. In 33% of cases, the type of anaesthesia was not specified [5]. In the present case, a 17-year-old woman with an ectopic tooth, which was tooth number 18, associated with a dentigerous cyst was treated under general anaesthesia. The main symptoms were swelling, pain, and right nasal obstruction, and only nasal discharge was absent from her symptoms in the triad given above.

According to Mavriqi L et al., among 34 reports, the most common presentations of ectopic upper third molars were associated with the posterior wall (24.13%), the lateral wall (22.41%), the medial wall (18.96%), the inferior wall (17.24%), and the orbital floor (15.51%). An ectopic third molar is relatively rare at the level of the antrum anterior wall (1.72%). In the present case, the ectopic tooth was in the right maxillary sinus, attached to the zygomatic bone, right under the orbital floor (superior lateral), which is a rare case [6]. In

some cases, it has been reported that, panoramic radiography is the preferred form of radiographic examination due to its precision in detecting these structures in ectopic cases and the low level of radiation the patient is exposed to. However, the major disadvantage of Two Dimensional (2D) panoramic radiography is the difficulty in interpreting the exact location of the ectopic tooth and the associated pathology because of the superimposition of different bony structures [2,4,5,7-10]. In a previous study, 3D examinations were performed in 33 patients, while 2D X-ray imaging was used in six other patients [5]. Due to its anatomical position between the oral and nasal cavities, the maxillary sinus is susceptible to invasion by pathogenic organisms through the oral cavity or the nasal ostium [8]. The CBCT assessment of this case helped in complete localisation of the ectopic third molar. This allowed the surgeons to avoid any surgical complications during the surgical procedure. Additionally, another reason for advocating for CBCT scanning is that the dentigerous cyst encountered in the present case, which the authors had not encountered in other cases, extended to the ethmoid sinuses. If CBCT had not been performed, this situation would have gone unnoticed, and it would have caused the lesion to recur later on [7,9]. The realisation of this situation indirectly showed the necessity of an endoscopic nasal approach.

Approximately 10-20% of sinusitis cases have a dental aetiology such that odontogenic sinusitis is generally caused by periodontitis, peri-implantitis, periapical pathology, or oroantral communication [10]. In terms of clinical symptoms, many patients with odontogenic sinusitis do not present with a maxillary toothache. The most common symptoms are facial pain, nasal obstruction, snoring, headache, acute sinus perforation, and swelling, which are symptoms similar to those of an infected ectopic tooth in the maxillary sinus [11,12]. In the present case, the patient gave a history of similar symptoms of pressure on the apical region of the teeth and the anterior wall of the maxillary sinus, resulting in pain, and nasal airflow declined on the right side. An ectopic tooth in the maxillary sinus may cause sinusitis, as well as, dentigerous cysts, keratocystic odontogenic tumours, odontomas, and bone tumours such as ossifying fibromas. Additionally, it may cause several complications such as blurred vision, oronasal fistula, facial pain, paranasal sinusitis, epistaxis, nasal septal deviation, nasal septal abscess, and nasolacrimal obstruction [3,8,11,13]. In the present case, the patient had an ectopic third molar surrounded by a dentigerous cyst without serious complications. The teeth that are the most commonly associated with a dentigerous cyst are mandibular third molars, maxillary canines, mandibular premolars, and very rarely, maxillary third molars. It is also important to completely remove all diseased antral tissues and thoroughly assess all resected soft tissue histologically with proper follow-up for one year to prevent recurrence as reported in the presented case [12,14].

In a recent meta-analysis, for the surgical procedures of 39 ectopic maxillary third molars, the Caldwell-Luc approach was performed in 77% of the cases, and the procedures were performed via transoral endoscopy in 10%. For the remaining patients, nasal endoscopy was used alone in 10%, while in 1 (3%) patient, the Le Fort I osteotomy approach was used [5]. The presented patient underwent Caldwell-Luc antrostomy and the complete enucleation of the cyst because this method allows the direct visualisation of the maxillary sinus, as well as, the instrumentation, irrigation, and removal of large objects, making it the treatment of choice for surgery. An endoscopic approach was performed also for drainage, transnasal excisions, and the visualisation of the ethmoid sinuses. The endoscopically assisted Caldwell-Luc approach is suitable for safer the instrumentation of the superolateral aspect of the maxillary sinus, allowing a direct line access for the visualisation of potential orbital floor defects [1,15]. In terms of drug prophylaxis, antibiotic therapy is often administered with amoxicillin or amoxicillin/clavulanate associated with a non-steroidal anti-inflammatory

protocol [6]. In the present case, the patient was instructed to take amoxicillin/clavulanate potassium (875/125 mg) 2 times/day and metronidazole (500 mg) 3 times/day for 5 days, as well as, antiseptic (povidone-iodine 7.5%) mouthwash 3 times/day for 7 days. Flurbiprofen (100 mg) was also prescribed postoperatively, to be taken as required, and no postoperative complication was observed.

CONCLUSION(S)

In conclusion, the location of the ectopic tooth and the spread of the associated cyst should be the most important guide in surgical planning. In the present case, the right maxillary ectopic third molar tooth with a dentigerous cyst, obstructing all maxillary and ethmoid sinuses was successfully extracted by Caldwell-Luc and nasal endoscopic surgeries. After postoperative medication, the patient recovered without any problems, and no complications were observed in her one year follow-up.

REFERENCES

- [1] Abd El-Fattah AM, Khafagy YW, El-Sisi H, Elkahwagi M, Ebada HA. Ectopic maxillary sinus third molar with dentigerous cyst in 11 patients: Tailored endoscopic-assisted approaches for a successful outcome. *Clin Otolaryngol* [Internet]. 2021 Sep 1 [cited 2022 Sep 24];46(5):1095-99. Available from: <https://pubmed.ncbi.nlm.nih.gov/33773043/>
- [2] Srinivasa Prasad T, Sujatha G, Niazi TM, Rajesh P. Dentigerous cyst associated with an ectopic third molar in the maxillary sinus: A rare entity. *Indian J Dent Res*. 2007;18(3):141-43.
- [3] Demirtas N, Kazancioglu HO, Ezirganli S. Ectopic tooth in the maxillary sinus diagnosed with an ophthalmic complication. *J Craniofac Surg* [Internet]. 2014 [cited 2022 Sep 24];25(4):e351-52. Available from: <https://pubmed.ncbi.nlm.nih.gov/25006943/>
- [4] Kasat VO, Karjodkar FR, Laddha RS. Dentigerous cyst associated with an ectopic third molar in the maxillary sinus: A case report and review of literature. *Contemp Clin Dent* [Internet]. 2012 [cited 2022 Nov 24];3(3):373. Available from: <https://pubmed.ncbi.nlm.nih.gov/25006943/>
- [5] Courtot R, Devoize L, Louvrier A, Pereira B, Caillet J, Meyer C, et al. Surgical approach of ectopic maxillary third molar avulsion: Systematic review and meta-analysis. *J Stomatol Oral Maxillofac Surg*. 2021;122(1):77-82.
- [6] Mavriqi L, Lorusso F, Tartaglia G, Inchingolo F, Scarano A. Transinusal pathway removal of an impacted third molar with an unusual approach: a case report and a systematic review of the literature. *Antibiotics* [Internet]. 2022 May 1 [cited 2023 Jan 18];11(5):658. Available from: <https://pubmed.ncbi.nlm.nih.gov/33773043/>
- [7] Júnior OLC, Moura LB, Sonego CL, Farias EOC de, Giongo CC, Fonseca AAR. Unusual case of sinusitis related to ectopic teeth in the maxillary sinus roof/orbital floor: a report. *Craniomaxillofac Trauma Reconstr* [Internet]. 2016 Sep [cited 2022 Dec 2];9(3):260. Available from: <https://pubmed.ncbi.nlm.nih.gov/25006943/>
- [8] Jendi SK. Ectopic Third Molar: A Hidden Cause For Maxillary Sinusitis-A Rare Case Report. *Indian J Otolaryngol Head Neck Surg* [Internet]. 2019 Oct 1 [cited 2022 Nov 23];71(Suppl 1):831. Available from: <https://pubmed.ncbi.nlm.nih.gov/33773043/>
- [9] Elmorsy K, Elsayed LK, Khateeb SM El. Case Report: Ectopic third molar in the maxillary sinus with infected dentigerous cyst assessed by cone beam CT. *F1000Research* [Internet]. 2020 Apr 16 [cited 2022 Nov 23];9:209. Available from: <https://pubmed.ncbi.nlm.nih.gov/33773043/>
- [10] Ibrahim MA, EL Orra S, Ramadan N, Lakis A, Dabbous M. Five ectopic teeth in the maxillary sinus: a rare cause of chronic sinusitis. *Cureus* [Internet]. 2022 Feb 14 [cited 2022 Nov 23];14(2):e22204. Available from: <https://pubmed.ncbi.nlm.nih.gov/33773043/>
- [11] López-Carriches C, López-Carriches I, Bryan RB-P. Odontogenic sinusitis caused by an inflammation of a dentigerous cyst and subsequent finding of a fibrous dysplasia. a case report. *Open Dent J* [Internet]. 2016 Dec 5 [cited 2022 Sep 24];10(1):647-55. Available from: <https://pubmed.ncbi.nlm.nih.gov/28077969/>
- [12] Thakur G, Nair PP, Shaji Thomas, Ahuja R, Kothari R. Unusual presentation of more common disease/injury: Dentigerous cyst associated with ectopic maxillary third molar in maxillary antrum. *BMJ Case Rep* [Internet]. 2011 [cited 2022 Dec 2];2011:bcr0220113873. Available from: <https://pubmed.ncbi.nlm.nih.gov/33773043/>
- [13] Sheethal HS, Rao K, Umadevi H, Chauhan K. Odontogenic keratocyst arising in the maxillary sinus: A rare case report. *J Oral Maxillofac Pathol* [Internet]. 2019 Feb 1 [cited 2023 Jan 18];23(Suppl 1):74. Available from: <https://pubmed.ncbi.nlm.nih.gov/33773043/>
- [14] Guruprasad Y, Chauhan D, Kura U. Infected dentigerous cyst of maxillary sinus arising from an ectopic third molar. *J Clin Imaging Sci* [Internet]. 2013 [cited 2022 Dec 4];3(Suppl 1):7. Available from: <https://pubmed.ncbi.nlm.nih.gov/33773043/>
- [15] Liao I, Lynch N, Hearn B, Cheng A. Endoscopically assisted modified Caldwell-Luc approach to enucleation of dentigerous cyst with ectopic tooth from the maxillary sinus. *J Craniofac Surg* [Internet]. 2018 [cited 2022 Dec 2];29(6):e568-70. Available from: <https://pubmed.ncbi.nlm.nih.gov/29762318/>

PARTICULARS OF CONTRIBUTORS:

1. Associate Professor, Department of Oral and Maxillofacial Surgery, Final International University, Nicosia, Turkey.
2. Associate Professor, Department of Otolaryngologist, Private ENT Clinic, Nicosia, Turkey.
3. Research Assistant, Department of Oral and Maxillofacial Surgery, Final International University, Nicosia, Turkey.

NAME, ADDRESS, E-MAIL ID OF THE CORRESPONDING AUTHOR:

Kani Bilginaylar,
Alpay Kelami Street, No:1, Ortakoy, Nicosia-0392, Mersin 10, Turkey
E-mail: kani_blgnylr@hotmail.com

AUTHOR DECLARATION:

- Financial or Other Competing Interests: None
- Was informed consent obtained from the subjects involved in the study? Yes
- For any images presented appropriate consent has been obtained from the subjects. Yes

PLAGIARISM CHECKING METHODS: [Jain H et al.]

- Plagiarism X-checker: Dec 17, 2022
- Manual Googling: Feb 03, 2023
- iThenticate Software: Feb 28, 2023 (20%)

ETYMOLOGY: Author Origin

Date of Submission: **Dec 15, 2022**

Date of Peer Review: **Jan 06, 2023**

Date of Acceptance: **Mar 01, 2023**

Date of Publishing: **May 01, 2023**