



Severe Kyphosis Patients with Tuberculosis and Chronic Obstructive Pulmonary Disease: A Case Report

Desdiani Desdiani ^{a,b*} and Flora Eka Sari ^c

^a Department of Pulmonology and Respiratory Medicine, Faculty of Medicine, IPB University, Bogor, Indonesia.

^b Jalan Raya Dramaga, Babakan, Kec. Dramaga, Bogor, West Java, Indonesia.

^c Department of Pulmonology and Respiratory Medicine, Faculty of Military Medicine, Universitas Pertahanan Republik Indonesia, Indonesia.

Authors' contributions

This work was carried out in collaboration between both authors. Both authors read and approved the final manuscript.

Article Information

DOI: <https://doi.org/10.9734/jammr/2024/v36i65447>

Open Peer Review History:

This journal follows the Advanced Open Peer Review policy. Identity of the Reviewers, Editor(s) and additional Reviewers, peer review comments, different versions of the manuscript, comments of the editors, etc are available here: <https://www.sdiarticle5.com/review-history/116955>

Case Report

Received: 10/03/2024

Accepted: 13/05/2024

Published: 16/05/2024

ABSTRACT

Background: Severe kyphosis in advanced age, with a higher incidence observed in women and in elderly males afflicted with pulmonary tuberculosis (TB) and chronic obstructive pulmonary disease (COPD) can pose a significant risk to their overall well-being and potentially endanger their lives.

Methods: A 59-year-old male with respiratory problem, chronic back pain, and walking disorder was admitted to the emergency room with symptoms of shortness of breath that had been worse in the previous three days. According to the patient's mother, the patient's chest had been bent or arched, curved anterior sternum, since he was three years old but had never been referred to a hospital or undergone any medical treatment. Anti-tuberculosis and COPD treatment with physiotherapy during the first 3 months was quite encouraging because now the patient can do light activities and work again.

*Corresponding author: E-mail: desdiani@ymail.com;

Cite as: Desdiani, D., & Sari, F. E. (2024). Severe Kyphosis Patients with Tuberculosis and Chronic Obstructive Pulmonary Disease: A Case Report. *Journal of Advances in Medicine and Medical Research*, 36(6), 23–29. <https://doi.org/10.9734/jammr/2024/v36i65447>

Results: Delays in spinal correction are caused by a lack of early detection capabilities from an early age and late referral to the hospital. Because of his advanced age, the patient was not able to have thoracic surgery; instead, he received thoracic manual treatment in addition to physiotherapy at a distant facility with restricted surgical capabilities. Rather, physiotherapy, which included thoracic corrective exercises and scapular posture. Correcting thoracic posture, enhancing structural alignment, and increasing thoracic rigidity are the main objectives of this activity.

Conclusion: Patients with severe cases of kyphosis require early detection of bone abnormalities by primary health center staff. Corrections can be made to prevent reduced body function, musculoskeletal disorders, and quality of life.

Keywords: Severe kyphosis; tuberculosis; COPD; physiotherapy.

1. INTRODUCTION

Severe kyphosis is defined as a curvature of the kyphosis angle that exceeds the usual range. Increased kyphosis angle is caused by decreased muscle strength and degenerative changes in the spine. Almost 40% of people with severe kyphosis may suffer from spine fractures [1-3]. In elder people, the prevalence of severe kyphosis ranges from 20% to 40%, with higher incidence observed in women [4,5]. Severe kyphosis was associated with negative health outcomes such as decreased lung function and physical ability, chronic back pain, a twofold increase in the risk of falling, and a worse quality of life [6].

According to the Global Tuberculosis Report 2020, Indonesia was responsible for 14% of all tuberculosis cases worldwide [7]. Back and chest pain are common symptoms of spinal tuberculosis [8,9]. Surgical interventions for spinal fractures such as vertebroplasty and kyphoplasty are undertaken because they are minimally invasive and have a sagittal corrective impact of about 70% [10,11]. Physiotherapy, which includes manual therapy, taping, and bracing, should always be the first line of treatment for thoracic Severe kyphosis, and it should be started as soon as feasible [12]. Thoracic Severe kyphosis therapy attempts to restore physical function, reduce pain, and reduce excessive anteroposterior curvature [13]. The resultant damage from COPD, combined with the aging process, will have a deleterious impact on the entire body in elderly adults with thoracic kyphosis [14,15]. We present severe kyphosis patients with tuberculosis and COPD in this study.

2. CASE SUMMARY

A 59-year-old male was admitted to the emergency room with symptoms of shortness of

breath that had been worse in the previous three days and complaints of shortness of breath for the previous year, which became worse when the patient undertook activities. The patient has been cough, fatigue, and chronic back discomfort. The patient denied loss of appetite, weight loss, or fever. He has been using a cane for many years and frequently falls if he does not use a cane. He had been smoking since he was 18 years old and worked as a parking attendant for more than 30 years at public fuel stations. According to the patient's mother, the patient's chest had been bent or arched since he was three years old but had never been referred to a hospital or undergone any medical treatment. Physical examination of the lungs revealed crackles, wheezing, and prolonged expiration, a heart rate of 110 beats per minute (bpm), respiratory rate of 28 bpm, oxygen saturation of 85% and it appear pectus carinatum. He was sent to intensive care unit and treated with nonbreathing mask oxygen therapy, NaCl 0.9% infusion, aminophylline, ipratropium bromide-albuterol sulfate inhalation, budesonide inhalation, methylprednisolone injection, levofloxacin, omeprazole, furosemide, digoxin, rifampicin, isoniazid, pyrazinamide, and ethambutol based on body weight. The blood work showed leukocytes 28,230 cells/ul, and the sputum examination/molecular quick test results were positive for tuberculosis. Fig. 1 shows a tenting right hemidiaphragm, curved anterior sternum and kyphotic thoracic vertebrae on a lateral chest x-ray. The patient's health improved after the fifth day of therapy and was discharged from the hospital after ten days of treatment. Due to the restricted resources in the hospital, the patient performed a Cobb angle measurement with a simple goniometer/ruler to measure the kyphosis curvature before leaving the hospital, and the results of the examination revealed that the thoracic flexion curve was more than 107 degrees. When this patient bends over, a hump is noticeable (Fig. 2a and 2b). Outpatient

treatment for tuberculosis and COPD is maintained. Due to the patient's age, limited hospital operating facilities for surgery, and refusal to be referred to a hospital with full facilities because it was too far away from his home, the patient finally underwent thoracic

manual physiotherapy and was evaluated after 3 months. The outcomes of the combination of antituberculosis and COPD medications, together with physiotherapy, are extremely positive, as the patient can now perform mild tasks and has resumed work.

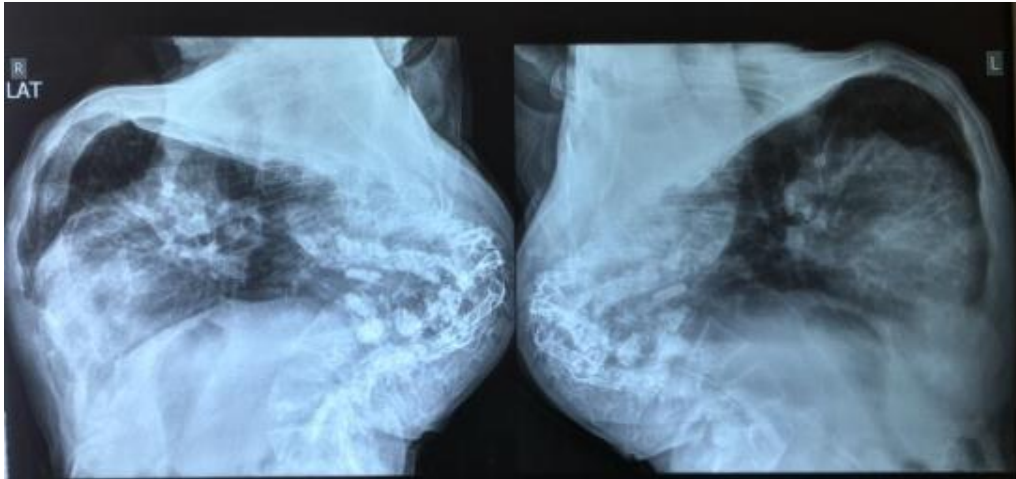


Fig. 1. Lateral chest X-ray

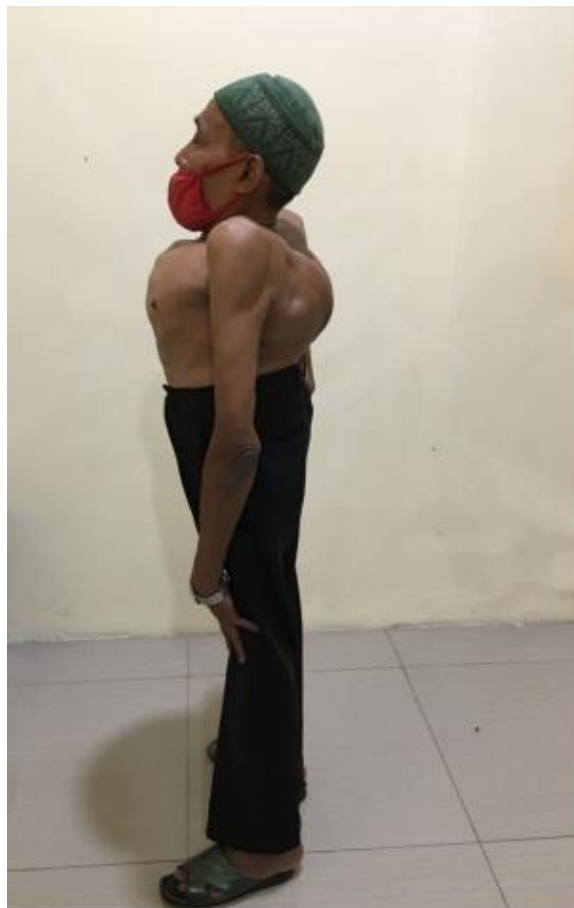

Fig. 2a. Hyperkyphosis from lateral view



Fig. 2b. A bump in hyperkyphosis patients, is visible when bending over

3. DISCUSSION

This is our first case, an elderly patient with severe kyphosis, pectus carinatum, TB, clinical COPD, and short stature. The patient's severe kyphosis had gone undetected and untreated since childhood. He was never advised to be referred to the hospital for medical treatment. According to Kado et al., severe kyphosis is more prevalent in women, and the majority of kyphosis angles increase with age [16]. Pectus carinatum (PC) is a congenital abnormality of the chest wall, prominent during puberty with the peak age being 16 to 18 years. It can present with other anomalies, such as kyphosis. PC and kyphosis can cause dyspnea, back pain, decreased endurance and can be corrected surgically or through bracing. Other surgical options are performed for cosmetic purposes, treating cardiopulmonary complications, and preventing progressive postural deformity [17].

We considered the possibility of genetic disorders such as Morquio A syndrome, also

called mucopolysaccharidosis IVA, is an extremely rare autosomal recessive disorder characterized as an "inborn error of metabolism", unpredictable in its age-sensitive nature, rate of progression, type and severity of symptoms. Initial symptoms were recognized at a mean age of 2.1 years. Common presenting features include short stature, kyphosis, genu valgum, and pectus carinatum. Over time, progression of the disease affects quality of life and survival prognosis [18]. Scheuermann's sickness is a juvenile form of severe kyphosis, defined by a defect in the cortical development plates of the vertebral bodies, which weakens the vertebral bodies and causes pinching, culminating at the end of growth and cartilage formation is no longer active [19]. We cannot carry out genetic examination, because limited hospital facilities, not covered by national insurance and the patient's financial problems.

This patient had suffered from chronic back pain for years and walked slowly, using a cane to avoid falling. He had smoked since 18 years old

and worked as a parking attendant at a public fuel station for more than 30 years. Thoracic severe kyphosis may result in musculoskeletal, neuromuscular, and sensory disorders, aging process progression, pain, dysfunction, breathing issues, restricted spine range of motion, osteoporotic fractures, reduced mobility, slower walking, poor balance, and exhaustion [20-23].

In this patient, a lateral chest x-ray revealed a tenting right hemidiaphragm and kyphotic thoracic vertebrae. Chen et al. Study was unable to measure the Cobb angle before surgery using an X-ray coronal sequence due to a calcified abscess, but they were able to measure the kyphosis angle with an X-ray sagittal sequence [24]. Cobb angle measurements were performed on this patient using a simple goniometer, which was regarded to be the most accurate approach to determining kyphosis curvature [25]. The superior vertebra of the fourth thoracic vertebrae (T4) is typically less visible due to the excessive protrusion of other components. As a result, the usual angle ranges from T4 to T12 [26].

Spinal tuberculosis often involves and destroys several adjacent vertebral bodies resulting in worsening kyphosis, can result in psychological, cardio-respiratory and neurological problems, especially if the kyphotic deformity is $>90^\circ$. Surgery is always necessary to relieve spinal cord compression and to treat neurological complications, back pain and dysfunction, and poor sagittal balance. However, they resulted in minimal correction of kyphosis with a high rate of complications [27].

Pain is common in people with chronic obstructive pulmonary disease (COPD) and the cause of back pain in COPD may be due to postural dysfunction, including increased thoracic kyphosis. Postural deviations are more present in COPD compared with those without lung disease but are not related to pain. Further research is needed to identify factors that contribute to these postural deviations [28].

In this situation, the patient was unable to undergo thoracic surgery due to his age, and the limited surgical facilities of the hospital. Instead, the patient was treated with antituberculosis and COPD medications, and physiotherapy, including thoracic correction exercises and scapular posture. The fundamental goals of this activity, which includes thoracic manual therapy and thoracic correction exercises, are to correct thoracic posture, improve structural alignment

and rigidity of the thorax. Scapular posture helps patients with thoracic severe kyphosis. When the kyphosis angle surpasses 80° , surgery may improve lung function and sagittal plane balance [29]. Frankel scores worsened in 3 patients and did not improve in 5 patients in Wong et al.'s trial with early surgical intervention in 16 patients [30]. According to Chen et al., severe kyphosis and spinal cord tuberculosis require surgery to relieve compression, and after several weeks of halo traction, excellent orthopedic surgical treatment results [31]. Prospective studies of kyphosis, show decreased lung function in both women and men. Amanda et al. reported severe kyphosis increases the risk of lung function decline, requiring intervention to prevent or slow the progression of kyphosis, thereby alleviating subsequent lung decline which is an important determinant of morbidity and mortality in the elderly [32].

Physiotherapy is usually the first line of treatment for thoracic severe kyphosis, and it should be started as soon as possible [12]. The primary goals of therapy for patients with thoracic severe kyphosis are to alleviate pain and improve physical function by eliminating excessive antero-posterior curvature. The early detection and treatment of severe kyphosis may reduce the incidence of fractures, falls, and functional deficits. Breathing exercises improve lung capacity and physical exertion tolerance. Gait training and balance workouts improve general fitness and reduce the likelihood of falling [13]. According to an international survey, patients with thoracic severe kyphosis react favorably to conservative treatment [33].

4. CONCLUSION

We feel this case may shed new light on the treatment of severe kyphosis with tuberculosis and COPD. We administered TB and COPD medication as well as physiotherapy thoracic manual treatment may improve structural alignment and stiffness of the thorax, because the patient declined to be referred due to his age, delayed treatment and restricted hospital facilities. Three months later, the patient's condition had improved clinically. Lessons learned in this case are the importance of health workers in primary health center screening and detecting bone abnormalities at an early age and immediately referring patients to the hospital with full facilities so that corrections can be made early to prevent decreased body function, musculoskeletal disorders, and quality of life.

CONSENT

As per international standards or university standards, patient(s) written consent has been collected and preserved by the author(s).

ETHICAL APPROVAL

As per international standards or university standards written ethical approval has been collected and preserved by the author(s).

COMPETING INTERESTS

Authors have declared that no competing interests exist.

REFERENCES

1. Baumgartner RN, Waters DL, Gallagher D, Morley JE, Garry PJ. Predictors of skeletal muscle mass in elderly men and women. *Mech. Aging Dev.* 1999;107:123–36. DOI: 10.1016/S0047-6374(98)00130-4
2. Hinman MR. Comparison of thoracic kyphosis and postural stiffness in younger and older women. *Spine J.* 2004;4:413–7. DOI: 10.1016/j.pinee.2004.01.002
3. Schneider DL, von Muhlen D, Barrett-Connor E, Sartoris DJ. Kyphosis do not equal vertebral fractures: The Rancho Bernardo study. *J Rheumatol.* 2004;31:747–52.
4. Kado DM, Huang MH, Karlamangla AS, Barrett Connor E, Greendale GA. Hyperkyphotic posture predictions mortality in older community-dwelling men and women: a prospective study. *O'clock Geriatr Soc.* 2004;52:1662-1667. Available:<http://dx.doi.org/10.1111/j.1532-5415.2004.52458.x>
5. Takahashi T, Ishida K, Hirose D, Nagano Y, Okumiya K, Nishinaga M, et al. Trunk deformity is associated with a reduction in outdoor activities of daily living and life satisfaction in community-dwelling older people. *Osteoporosis Int.* 2005;16:273-279.
6. Koele MC, Lems WF, Willems HC. The clinical relevance of Severe kyphosis : A narrative review. *Front Endocrinol.* 2020;11(5):1-7
7. Global Tuberculosis Report. WHO, 2020. Available:<https://www.who.int/publications/i/item/9789240013131>
8. Moon M. Tuberculosis of the spine. Controversies and a new challenge. *Spine.* 1997;22(15):1791 – 7. DOI: 10.1097/00007632-199708010-00022
9. Diwakar L, Ghaffar N, Hare A, Lynn W, Ash S. Low back pain: thoughts of tuberculosis. *BMJ.* 2006;333(7560):201. DOI: 10.1136/bmj.333.7560.201
10. de Nijs R. Spinal tuberculosis. *Lancet.* 2011;378(9807):e18. DOI: 10.1016/S0140-6736(11)61482-7
11. Debnath U, McConnell J, Kumar S. Single-stage combined anterior corpectomy and posterior instrumented fusion in tuberculous spondylitis with varying degrees of neurological deficit. *Int J Spine Surg.* 2021;15(13):600–11. DOI: 10.14444/8081
12. de Mauroy JC, Vallèse P, Fender P, Lecante C. Historical Lyonnaise brace treatment for adolescent Severe kyphosis. Results of 272 cases reviewed minimum 2 years after removal of the brace. *Scoliosis.* 2010;5(1):O69.
13. Katzman WB, Wanek L, Shepherd JA, Sellmeyer DE. Age-related Severe kyphosis: its causes, consequences, and management. *Journal of Orthopedic & Sports Physical Therapy.* 2010;40(6):352-60.
14. Goncalves MA, Rodovalho PL, Bellini AJ, Bruggemann AKV, Mazo GZ, Paulin E. Thoracic kyphosis comparison between a patient with chronic obstructive pulmonary disease and a healthy individual by flexicurve method. *Fisioter Pesq.* 2015;22(3):333-9
15. J Van Dort M, Driessen JHM, Romme EAPM, Geusens P, Willems PC, Smeenk FWJM, Wouters EFM, van den Bergh JPW. Thoracic kyphosis on chest CT scans is associated with incident vertebral fractures in smokers. *J Bone Miner Res.* 2019;34(5):e3672.
16. Kado DM, Prenovost K, Crandall C. Narrative review: Severe kyphosis in older persons. *Ann Intern Med.* 2007;147(5):330-8
17. Iwaiwi B, Shaqqura BH, Sabbah A, Akar FEA. Combined surgical correction of pectus carinatum and juvenile kyphosis. *Interact Cardiovasc Thorac Surg.* 2022;35(2):ivac087. Available:<https://doi.org/10.1093/icvts/ivac087A>
18. Yamauchi K, Hirano D, Wada M, Ida H. Pectus carinatum as the key to early diagnosis of Morquio A syndrome: a case report. *J Med Case Rep.* 2021;15(1):150. DOI: 10.1186/s13256-021-02737-1

19. de Mauroy JC. Kyphosis physiotherapy from childhood to old age. Physical Therapy Perspective in The 21s Century, IntechOpen; 2012.
20. Lewis JS, Valentine RE. Clinical measurement of the thoracic kyphosis. A study of the intra-rater reliability in subjects with and without shoulder pain. BMC Musculoskelet Disord. 2010; 11:39.
21. Edmondston SJ, Singer KP. Thoracic spine: anatomical and biomechanical considerations for manual therapy. Manual Therapy. 1997;2(3):132-43.
22. Culham EG, Jimenez HA, King CE. Thoracic kyphosis, rib mobility, and lung volumes in normal women and women with osteoporosis. Spine. 1994;19(11): 1250-5.
23. Greendale GA, Nili NS, Huang MH, Seeger L, Karlamangla AS. The reliability and validity of three non-radiological measures of thoracic kyphosis and their relationship to the standing radiological Cobb angle. Osteoporosis International. 2011;22(6): 1897-905.
24. Chen L, Liu C, Ye Z, Liang T, Huang S, Chen J, et al. Multiple spinal tuberculosis with severe kyphosis: a case report. Frontiers in Surgery. 2022;9:815514. DOI:10.3389/fsurg.2022.815514
25. Roghani T, Zavieh MK, Manshadi FD, King N, Katzman W. Age-related Severe kyphosis: update of its potential causes and clinical impacts-narrative review. Aging Clin Exp Res. 2016;29:567–77. DOI: 10.1007/s40520-016-0617-3
26. Fon GT, Pitt MJ, Thies AC Jr. Thoracic kyphosis: range in normal subjects. Am J Roentgenol. 1980;134:979–83. DOI: 10.2214/ajr.134.5.979
27. Qi L , Zhao Y, Xu B, Li C, Wang Y. Two-stage treatment for severe spinal kyphotic deformity secondary to tuberculosis: halo-pelvic traction followed by a posterior-only approach correction. BMC Musculoskelet Disord. 2022;23(1):991. DOI: 10.1186/s12891-022-05974-7
28. Lee A, Zabjek K, Goldstein R, Brooks D. Postural abnormalities in people with chronic obstructive pulmonary disease (COPD). Eur. Respir J. 2016;48:PA1344. DOI: 10.1183/13993003.congress-2016.PA1344
29. Shahi P, Chadha M, Sehgal A, Sudan A, Meena U, Bansal K, Batheja D. Sagittal balance, pulmonary function, and spinopelvic parameters in severe post tubercular thoracic kyphosis. Asian Spine J; 2021. DOI: 10.31616/asj.2020.0464
30. Wong YW, Samartzis D, Cheung KMC, Luk K. Tuberculosis of the spine with severe angular kyphosis: mean 34-year post-operative follow-up shows that prevention is better than salvage. Bone Joint J. 2017;10:1381–8. DOI: 10.1302/0301-620X.99B10.BJJ-2017-0148.R1
31. Wang L, Chen QL, Lu TS, Yao SD, Pu XW, Luo CS. Study on safety and clinical efficacy of osteotomy after halo pelvic traction in severe scoliosis accompanied with split cord malformation. Zhonghua Wai Ke Za Zhi. 2021;59(5):370–7. DOI: 10.3760/cma.j.cn112139-20200904-00686
32. Lorbergs AL, O'Connor GT, Zhou Y, Thomas G, Trivison TG, Kiel DP, Adrienne Cupples LA. Severity of Kyphosis and Decline in Lung Function: The Framingham Study. J Gerontol A Biol Sci Med Sci. 2017;72(5):689–694. DOI:10.1093/gerona/glw124
33. Weiss H, Turnbull D. Kyphosis (Physical and technical rehabilitation of patients with Scheuermann's disease and kyphosis). International encyclopedia of rehabilitation; 2010. Available:https://www.physio-pedia.com/Scheuermann%27s_Kyphosis

© Copyright (2024): Author(s). The licensee is the journal publisher. This is an Open Access article distributed under the terms of the Creative Commons Attribution License (<http://creativecommons.org/licenses/by/4.0>), which permits unrestricted use, distribution, and reproduction in any medium, provided the original work is properly cited.

Peer-review history:

The peer review history for this paper can be accessed here:

<https://www.sdiarticle5.com/review-history/116955>