



## Role of melatonin in preventing thioacetamide-induced liver injury in rats

Abdou, S.E.<sup>a</sup>, Taha, N.M.<sup>b</sup>, Lebda, M.A.<sup>b</sup>, El Hoffy, H.R.<sup>a</sup>, Hashem, A.E.<sup>b</sup>

<sup>a</sup>Department of Biochemistry, Animal Health Institute, Damanhour Branch

<sup>b</sup>Department of Biochemistry, Faculty of Veterinary Medicine, Alexandria University

### ABSTRACT

The liver is a vital organ necessary for survival, synthesizing crucial molecules including cholesterol, glucose, and fatty acids. Moreover, it makes most plasma proteins including albumin, so its injury or damage leads to disturbance of their blood concentration. Thioacetamide (TAA) established liver fibrosis model with a histopathological appearance that is similar to human cirrhosis however, melatonin considered as one of anti-fibrotic agents through its anti-inflammatory and antioxidant functions, so we aimed to investigate the possible correction role of melatonin on altered serum proteins and liver histopathology on rats with induced liver injury. Sixty male albino rats were classified to equal 4 groups as follows: control, melatonin group (5mg/kg b.w/i.p), TAA group (150 mg/kg b.w/i.p) and TAA + melatonin group after 60 days, the animals were anesthetized to collect blood samples for determination of serum protein concentrations, and liver tissues were collected for histopathological examination. Key finding, liver injury induced by TAA caused marked decrease on serum protein and albumin, this injury was confirmed by histopathological examination that showed interlobular and intralobular cirrhosis associated with severe degree of hepatic vacuolation, On the other hand melatonin successfully improved the serious effects of TAA on liver function through ameliorating the decrease in total protein and albumin concentration along with restoring altered histopathological changes toward normal again. Our study concluded that co-treatment with melatonin may be favorable in protection from hepatic injury caused by TAA.

**Keywords:** Liver fibrosis; Total protein; Histopathology

### 1. Introduction

The liver is a multifunctional vital organ with the primary role in the maintenance of body homeostasis. Among the various liver functions are plasma protein synthesis (Tacke et al., 2009), processing dead red blood cells, detoxification (Yu et al., 2011) and glucose and lipid metabolism (Liu et al., 2012). The crucial role of the liver in maintaining human health status means that liver diseases can severely affect health status and threaten human life (Aberg et al., 2009). Oxidative stress is the primary cause of liver damage in many conditions such as toxin exposures and liver ischemia (Stehbens, 2003). Overproduction of reactive oxygen species (ROS) and nitrogen species, together with decreasing of antioxidant protection in these pathological conditions, lead to lipid peroxidation and mitochondrial dysfunction that disturbs various cellular functions (Fang et al., 2002) and resulted in cirrhosis (Kitada et al., 2001). Hepatic fibrosis is the wound response to chronic hepatic injury, including alcohol abuse, viral infection, and cholestasis. It is characterized by excessive production and deposition of extracellular matrix (ECM) molecules. It has been

established that hepatic stellate cells (HSC) are the primary ECM-producing cell type during hepatic fibrogenesis. TAA was originally used as a fungicide (Zhou et al., 2006); TAA is a weak carcinogen that mainly affects the liver and kidney (Bataller and Brenner, 2005). TAA has been considered to be an inducer of liver fibrosis and cirrhosis in rats histologically similar to that caused by human virus C fibrosis (Al-Attar, 2011). It induces liver fibrosis due to excessive lipid peroxidation and the exhaustion of antioxidant state (Abul et al., 2002).

Melatonin (N-acetyl-5-methoxytryptamine), synthesized from the mammalian pineal gland during the night, (Stehle et al., 2011). Also, it found in many other tissues as gastric, intestinal mucosa and liver (Konturek et al., 2007), has antioxidant properties (Reiter et al., 2016) and regulates physiological processes such as immune defense, (Calvo et al., 2013) metabolic syndrome (Kitagawa et al., 2012) and lipid profiles (Kozirog et al., 2011). Recent studies showed that melatonin exerts its cytoprotective effects in various experimental models of acute liver injury and reduces fibroblast proliferation and collagen synthesis (Tahan et al., 2004), indicating that melatonin may have therapeutic effects on acute and chronic liver injury (Hong et al., 2009; Martinez-Martinez et al., 2014). Melatonin antioxidant effect is attributable to the structure of its molecule, the presence of O-methyl and N-acetyl groups, which enables it to be as a hydrophilic and hydrophobic antioxidant. Melatonin deactivates the hydroxyl radical, singlet oxygen, nitrogen oxide, hydrogen peroxide and inhibits the peroxidation of lipids (Gulcin et al., 2003). Moreover, it, stimulate glutathione (the essential cellular antioxidant) synthesis and regeneration (Tahan et al., 2004). Furthermore, melatonin reduces the level of proinflammatory cytokines, such as tumor necrosis factor alpha (TNF- $\alpha$ ) and interleukin 1beta (IL-1 $\beta$ ) (Sidhu et al., 2010). It modulates several molecular pathways of inflammation (Borges et al., 2015). So, we aimed to explore the protective role of melatonin against TAA-induced liver injury.

### 2. Material and methods

#### 2.1. Animals

This study was carried out at the Faculty of Veterinary Medicine, Alexandria University. A total of 60 male albino rats weighing 150 $\pm$ 20 were purchased from Animal Breeding Unit, Medical Research Institute, Alexandria University. The Rats were kept in clean metal cages (15 rats/cage). They were given a basal diet and water *ad libitum*. All animals were housed under the mentioned environmental condition for two weeks for acclimatization and to ensure normal growth and behavior. The international ethical guidelines for the care and use of laboratory animals were performed to handle the animals and the experimental procedures were approved by the Experimental Animal Use and Ethics Committee at the Faculty of Veterinary Medicine, Alexandria University, Egypt.

#### 2.2. Chemicals and Reagents

Thioacetamide (TAA) was purchased from Biotechnology chemical Co., Egypt. Melatonin was purchased from Jamieson laboratories- Canada N8W. Sterile sodium chloride solution and Formalin were from El-Goumhouria Company for trading medicines, Alexandria, Egypt. Kits for Total protein and Albumin were from Vitro, Science Co., Egypt

#### 2.3. Experimental protocol

The rats were randomly divided into four equal groups (15 rats each) as

\*Corresponding author:

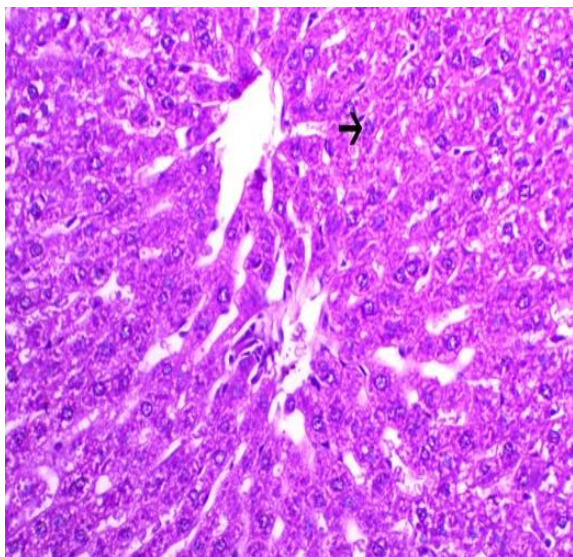
E-mail address: [suzan8527@yahoo.com](mailto:suzan8527@yahoo.com)

Faculty of veterinary medicine Alexandria University., Egypt

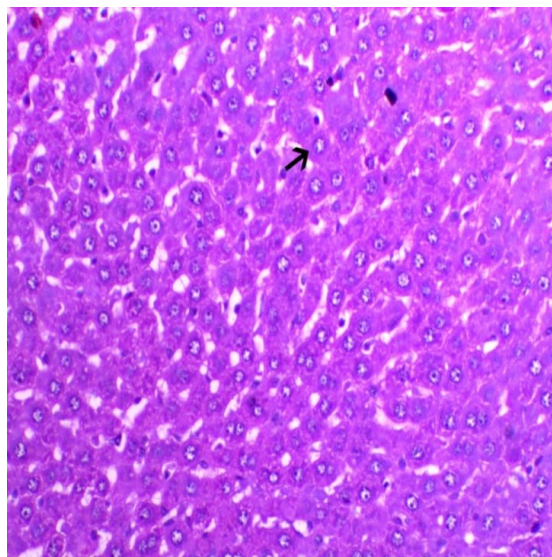
P ISSN: 2636-3003 EISSN: 2636-2996

DOI: 10.5455/DJVS.42702

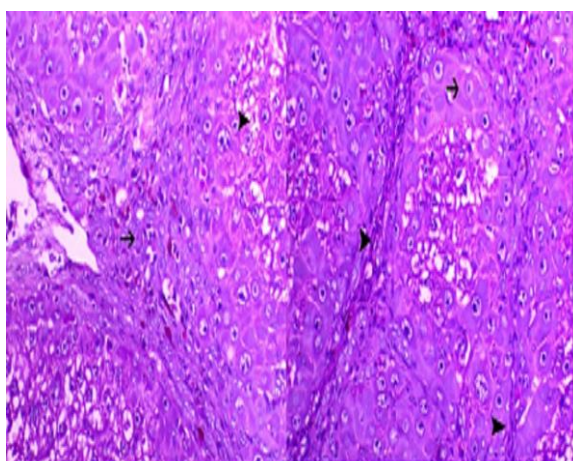
Received: May 28, 2019; Received in revised form: June 15, 2019; accepted: June 22, 2019.



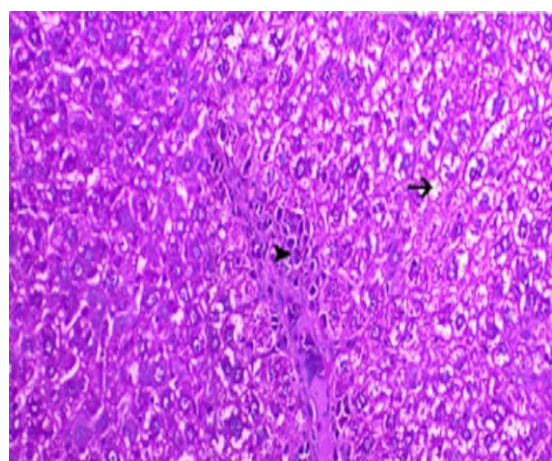
**Figure 1.** Liver of control animal showing normal hepatocytes arranged in cords, H&E, × 200.



**Figure 2.** Liver of melatonin-treated animal showing normal hepatocytes (arrow), H&E, × 200.



**Figure 3.** Liver of TAA-treated animal marked periportal fibrosis (arrowhead), giving features of interlobular and intralobular cirrhosis associated with marked hepatic regeneration (arrow) and severe degree of hepatic vacuolation (tailed-arrow), H&E, × 200.



**Figure 4.** Liver of (TAA+melatonin)-treated animal showing mild periportal hepatic vacuolation (arrowhead) with moderate vacuolation (arrow), H&E, ×200.

**Table 1:** Effect of melatonin and/or thioacetamide on serum protein concentrations in rats with induced liver injury

Group	Total protein (g/dl)	Albumin (g/dl)	Globulin (g/dl)	Albumin to globulin ratio
Control	5.20 ± 0.15 <sup>a</sup>	3.60 ± 0.05 <sup>a</sup>	1.60 ± 0.20 <sup>a</sup>	2.43 ± 0.36 <sup>a</sup>
Melatonin	4.91 ± 0.14 <sup>ab</sup>	2.96 ± 0.14 <sup>b</sup>	1.96 ± 0.19 <sup>a</sup>	1.69 ± 0.32 <sup>a</sup>
Thioacetamide	4.45 ± 0.15 <sup>b</sup>	2.78 ± 0.11 <sup>b</sup>	1.68 ± 0.13 <sup>a</sup>	1.72 ± 0.13 <sup>a</sup>
Melatonin and Thioacetamide	4.90 ± 0.15 <sup>ab</sup>	2.90 ± 0.14 <sup>b</sup>	2.00 ± 0.22 <sup>a</sup>	1.69 ± 0.26 <sup>a</sup>

Values are means ± standard errors.  
Means without a common superscript in a column differ significantly (P ≤ 0.05).

Follow;

Group I (control)	Was treated with 0.9% NaCl solution in a dose of 1ml/ rat
Group II (melatonin)	Was received an intraperitoneal injection of melatonin in a dose of (5 mg/kg B.W) once daily for 8 weeks according to Ahmed et al., (2016).
Group III (thioacetamide)	Was received an intraperitoneal injection of TAA in a dose of (150 mg/kg B.W) three times a week for 8 weeks according to Ahmed et al., (2016).
Group IV (melatonin and thioacetamide)	The rats were received simultaneously intraperitoneal injection of TAA together with melatonin with the same previous doses and method as mentioned before.

## 2.2. Blood samples

At the end of the experiment, the animals were left overnight fasting, then the blood samples were collected from the orbital plexuses of the eye under effect of anesthesia into clean tubes then left to be clotted, the animals then were sacrificed by decapitation; all blood samples were centrifuged at 3000 rpm for 10 min at 4 °C to obtain cleared and non-hemolyzed sera then samples were transferred to Eppendorf tubes and stored at -20 °C until analysis.

## 2.3. Tissue samples

After decapitation, livers were removed from rats in all groups, washed with ice-cold saline then blotted with filter paper; the liver of each animal was fixed in 10 % formalin solution for histopathological examination (Drury and Wallington, 1980).

## 2.4. Biochemical analysis

Estimation of total protein (Buccolo, 1973), albumin (Doumas, 1971), globulin (Coles, 1974).

## 2.5. Statistical analysis

ANOVA; one-way analysis of variance was used. SPSS program was used to perform all calculation and analysis. Data were expressed as means ± standard error (Means ± SE). P<0.05 was set as statistical significance (SAS, 2004).

## 3. Results

### 3.1. Biochemical analysis

Effect of melatonin and/or thioacetamide on serum protein concentrations in rats with induced liver injury. Table (1) cleared that there was a significant decrease in serum total protein and albumin in thioacetamide treated the group as compared to control group, while rats with induced liver injury and co-treated with melatonin showed significant improvement in total protein and albumin concentration as compared to thioacetamide treated group.

### 3.2. Histopathological findings

Liver of control and melatonin-treated group showed the normal histological appearance of hepatocyte and blood vessels (Figs 1 and 2). However, The microscopical findings of TAA-treated group exhibited marked and diffuse hepatic vacuolation, marked periportal fibrosis, oval cell hyperplasia, giving features of interlobular and intralobular cirrhosis associated with marked hepatic regeneration and severe degree of hepatic vacuolation (Fig 3), while the treatment by melatonin with TAA improved the histopathological appearance of hepatocyte and protect it from damaging induced by TAA as there was mild periportal hepatic vacuolation (arrowhead) (Fig 4).

## 4. Discussion

Hepatic fibrosis is traditionally defined as a progressive pathological process involving multiple cellular and molecular events that led ultimately to deposition of excess matrix proteins in the extracellular space including collagen and fibronectin (Iredale, 2008). It occurred in response to chronic injury in response to a variety insults, including viral hepatitis (A, B, C, D), alcohol abuse, drugs and metabolic diseases (Friedman, 2003). TAA is hepatotoxic that causes centrilobular necrosis with a subsequent regenerative response of liver leading to liver cirrhosis and hepatocarcinoma (Stankov'a et al., 2010).

Our current study revealed that there was significant decrease in total protein and albumin in TAA treated group this may be attributed to the damaged hepatocyte that became unable to metabolize protein or due to increased protein catabolism or amino acid degradation which agree with Mi-Ok and Jeon-Ok, (2010); Alshawsh et al., (2011) who recorded that, serum albumin concentration was reduced due to protein synthesis disruption in rats liver. Additionally, the decreased level of albumin or hypoalbuminemia and total protein in TAA control rats could be due to malnutrition related to liver cirrhosis (Nkosi et al., 2005). This came in harmony with our histopathological findings that showed inflammation and necrosis of hepatocyte (fig 3). On the other hand, melatonin showed the hepatoprotective effect as its improved serum protein and albumin concentrations. This came in accordance with Abdel-Wahab, (2012) who found that using melatonin at a dose of 5 mg/kg was able to attenuate the decrease in total proteins, reducing oxidative stress, and improving

histological changes as there was mild vacuolation, owing to melatonin antifibrotic effect, and may be due to its anti-inflammatory and antioxidant and activities.

## Conflict of interests

The authors have not declared any conflict of interests.

## References

- Abdel-Wahab, W.M.,2012. AICl3-induced toxicity and oxidative stress in liver of male rats: Protection by melatonin. *Life Sci. J.*, 9, 1173–1182.
- Aberg, F., Rissanen, A.M., Sintonen, H.,Roine, R.P., Höckerstedt, K., Isoniemi, H. 2009.Health-related quality of life and employment status of liver transplantpatients. *Liver Transp.* 15, 64–72.
- Abul, H., Mathew, T.C., Dashti, H.M., Al-Bader, A., 2002.Level of superoxide dismutase, glutathione peroxidase and uric acid in thioacetamide-induced cirrhotic rats. *Anat. Histol. Embryol.*, 31, 66-71.
- Ahmed, A. A., Ahmad, A. E., Ehab, M. H., 2016. Study of the Effects of Melatonin on Experimentally Induced Hepatic Fibrogenesis in Rats.*Intern. J. Adv. Res.* 4 (1), 1187- 1197
- Al-Attar, A.M., 2011.Hepatoprotective influence of vitamin C on thioacetamide-induced liver cirrhosis in Wistar male rats. *J. Pharmacol. Toxicol.*, 6 (3), 218- 233
- Alshawsh, M.A., Abdulla, M.A., Ismail S., Amin, Z.A., 2011. Hepatoprotective Effects of Orthosiphonstamineus Extract on Thioacetamide-Induced Liver Cirrhosis in Rats. *Evidence-Based Comp. Altern. Med.*, 1:6.
- Bataller, R., Brenner, D. A., 2005.Liver fibrosis. *J. Clin. Invest.*, 115, 209-218.
- Borges, L.D.A. S., Dermargos, A., DA, Silva, Junior, E.P. et al., 2015. Melatonin decreases muscular oxidative stress and inflammation induced by strenuous exercise and stimulates growth factor synthesis. *J Pineal Res.*, 58, 166– 172.
- Buccolo, G., 1973. Quantitative determination of serum triglycerides by use of enzymes. *Clin. Chem.*, 19, 476-548.
- Calvo, J.R., Gonzalez-Yanes, C., Maldonado, M. D., 2013. The role of melatonin in the cells of the innate immunity: a review. *J. Pineal Res.* 55, 103–120.
- Coles, E.H., 1974. Liver function in Veterinary Clinical Pathology, 2<sup>nd</sup> ed. W. B Saunders Company, Philadelphia and London. PP, 211–213.
- Doumas, B.T., 1971. Albumin standards and the measurement of serum albumin with bromocresol green. *J. Clin. Chem. Acta.* 31, 87- 96.
- Drury, R.A.B., and Wallington, E.A., 1980.Preparation and Fixation of Tissues in Carleton's Histological Technique, fourth ed. Oxford University Press, Oxford.
- Fang, Y.Z., Yang, S. and Wu, G., 2002. Free radicals, antioxidants, and nutrition. *Nut.*, 18 (10), 872–879.
- Friedman, S.L., 2003.Liver fibrosis from bench to bedside. *J. Hepatol.* 38, S38-S53.
- Gulcin, I., Buyukokuroglu, M.E., Kufrevioglu, O., 2003. Metal chelating and hydrogen peroxide scavenging effects of melatonin. *J. Pineal Res.* 34, 278-281.
- Hong, R.T., Xu, J.M., Mei, Q., 2009. Melatonin ameliorates experimental hepatic fibrosis induced by carbon tetrachloride in rats, *World J. Gastroenterol.*, 15 (12), 1452–1458.
- Iredale, J., 2008. Defining therapeutic targets for liver fibrosis: Exploiting the biology of inflammation and repair. *Pharmacol. Res.* 58, 129-136.
- Kitada, T., Seki, S., Iwai, S., Yamada, T., Sakaguchi, H., Wakasa, K., 2001.In situ detection of oxidative DNA damage hydroxydeoxyguanosine, in chronic human liver disease. *J. Hepatol.*, 35, 613–618.
- Kitagawa, A., Ohta, Y., Ohashi, K., 2012. Melatonin improves metabolic syndrome induced by high fructose intake in rats. *J. Pineal Res.* 52, 403–413.
- Konturek, S.J., Konturek, P.C., Brzozowski, T., Bubenik, G.A., 2007.Role of melatonin in upper gastrointestinal tract. *J. Physiol. Pharmacol.*, 58 (Suppl. 6), 23-52.
- Kozirog, M., Poliwczak, A.R., Duchnowicz, P., et al., 2011. Melatonin treatmentimproves blood pressure, lipid profile, and parameters of oxidative stress in patients with metabolic syndrome. *J. Pineal Res.*, 50(3), 261–6.
- Liu, Q., Yuan, B., Lo, K.A., Patterson, H.C., Sun, Y., Lodish, H.F., 2012.Adiponectin regulates expression of hepatic genes critical for glucose and lipid metabolism. *J. Proc. Nat. Acad. Sci.*, 109, 14568– 14641
- Martinez-Martinez, E., Jurado-lopez, R., Valero-munoz, M. et al., 2014. Leptin induces cardiac fibrosis through galectin-3, mTOR and oxidative stress: potential role in obesity. *J Hypertension*, 32, 1104–1114.

- Mi-Ok, S., and Jeon-Ok, M., 2010. Effect of dietary supplementation of grape skin and seeds on liver fibrosis induced by dimethylnitrosamine in rats. *Nutr. Res. Pract.*, 4, 369-374.
- Nkosi C.Z., Opoku A.R., Terblanche S.E., 2005. Effect of pump-kin seed (Cucurbitapepo) protein isolate on the activity levels of certain plasma enzymes in CCl4-induced liver injury in low-protein fed rats. *Phytother. Res.*, 19 (4), 341-345.
- Reiter, R.J., Mayo, J.C., Tan, D.X., *et al.*, 2016. Melatonin as an antioxidant: under promises but over delivers. *J. Pineal. Res.*, 61, 253-278.
- SAS, 2004. (statistical analysis system), statistical user's Guide. INT., Cary, NC. USA.
- Sidhu, S., Pandhi, P., Malhotra, S., Vaiphei, K., Khanduja, K.L., 2010. Melatonin treatment is beneficial in pancreatic repair process after experimental acute pancreatitis. *Eur. J. Pharmacol.*, 628, 282-289.
- Stankov'a, P., Ku'cera, O., Lotkov'a, H., Rou\_sar, T., Endlicher, R., Cervinkov'a, Z., 2010. The toxic effect of thioacetamide on rat liver *in vitro*. *Toxicol. Vitro.*, 24, 2097-103.
- Stehbens, W.E., 2003. Oxidative stress, toxic hepatitis, and antioxidants with particular emphasis on zinc. *Exp. Mol. Pathol.*, 75, 265-276.
- Stehle, J.H., Saade, A., Rawashdeh, O., *et al.*, 2011. A survey of molecular details in the human pineal gland in the light of phylogeny, structure, function and chronobiological diseases. *J. Pineal Res.*, 51, 17-43.
- Tacke, F., Luedde, T., Trautwein, C., 2009. Inflammatory pathways in liver homeostasis and liver injury. *Clin. Rev. J. Allergy Immunol.*, 36, 4 - 12
- Tahan, V., Ozaras, R. O., Canbakan, B., *et al.*, 2004. Melatonin reduces dimethylnitrosamine-induced liver fibrosis. *J. Pineal. Res.*, 37, 78-84.
- Yu, Y.D., Kim, K.H., Lee, S.G., Choi, S.Y., Kim, Y.C., Byun, K.S., Cha, I.H., Park, K.Y., Cho, C.H., Choi, D.H., 2011. Hepatic differentiation from human embryonic stem cells using stromal cells. *J. Surg. Res.*, 170, e253 - e261
- Zhou, H.Z., Swanson, R.A., Simonis, U., Ma, X., Cecchini, G., Gray, M.O., 2006. Poly (ADP-ribose) polymerase-1 hyperactivation and impairment of mitochondrial respiratory chain complex I function in reperfused mouse hearts. *Amer. J. Physiol.- Heart Circ. Physiol.*, 291, H714-23.