

Intramural Plexiform Hemangiomatous Proliferation: An Uncommon Vascular Variant in Unicystic Ameloblastoma

KARTHIKEYA PATIL¹, CJ SANJAY², SREESHYLA HUCHANAHALLI SHESHANNA³, NAGBHUSHANA DOGGALLI⁴, ESWARI SOLAYAPPAN⁵



ABSTRACT

Ameloblastoma are the benign, locally aggressive, slow growing solid or cystic neoplasms of the jaws containing odontogenic epithelium in a connective tissue stroma. Their polymorphous nature is reflected by the diversity of known histological patterns of presentation. The hemangiomatous ameloblastoma is the less commonly encountered histological pattern of ameloblastoma with increased vascularity. The presence of ameloblastoma in the maxillary area is rare entity, and the hemangiomatous variation of unicystic ameloblastoma in the anterior maxillary region has never been recorded in the literature. Authors hereby, present a case of a 22-year-old man who complained of swelling in the upper front tooth region with buccal cortical expansion and wispy trabeculation. This study is noteworthy since, it is the first to reveal the hemangiomatous type of unicystic ameloblastoma in the maxillary anterior region.

Keywords: Cysts, Maxilla, Odontogenic Tumour, Pathology

CASE REPORT

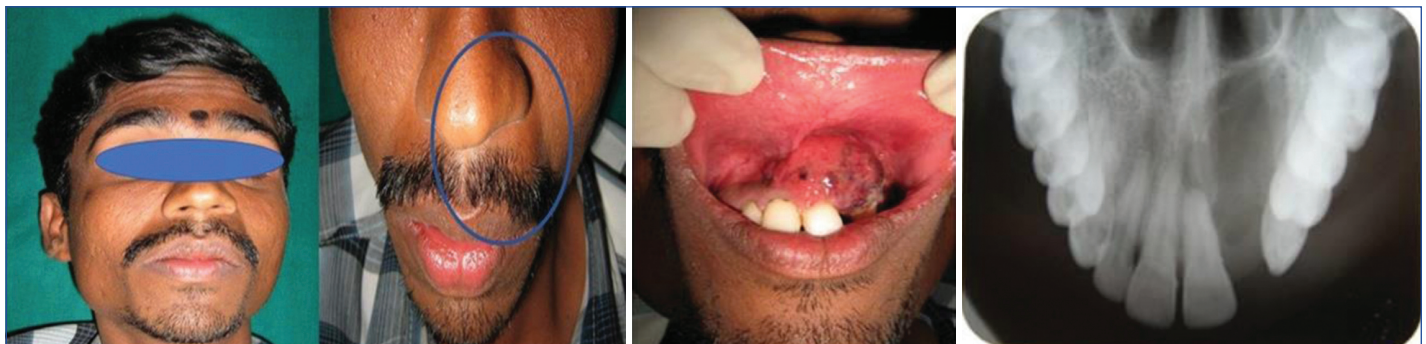
A 22-year-old male patient reported with a complaint of swelling in the upper front teeth region since a year. Patient gave a history of swelling which initiated two years back and was diagnosed as radicular cyst with relation to upper left lateral incisor which was extracted in private hospital. Extraoral examination revealed a solitary diffuse swelling of about 2x2 cm in size involving the left lateral half of the upper lip extending superiorly from the left ala of the nose and inferiorly towards the vermilion border of the lip causing obliteration of the left nasolabial fold [Table/Fig-1]. The swelling was non tender, soft in consistency and fixed to the underlying structures.

Intraoral examination revealed a solitary, lobulated, well-defined swelling on the labial aspect of 12, 11, 21 and 23 measuring 4x3 cm in size. In maxilla tooth number 22 was missing and extracted before two years which was diagnosed as radicular cyst. Mucosa over the swelling appeared erythematous and purplish [Table/Fig-2]. Maxillary cross-sectional occlusal view exhibited a well-defined unilocular radiolucency in relation to 21, 23, 24, 25 surrounded by a thick sclerotic border [Table/Fig-3]. There was buccal cortical expansion in relation to 23, 24 and 25 with coarse and wispy trabeculation. The internal structure was homogeneously radiolucent. Provisional diagnosis was given as residual cyst with relation to 22. Differential diagnosis was given as dentigerous cyst, adenomatoid odontogenic tumour and odontogenic keratocyst.

The patient was advised to undergo enucleation of the lesion which was performed and it was subjected to microscopic examination. Histopathology of the lesion showed presence of cystic epithelium lined by ameloblast-like cells showing hyperchromatic and palisaded basal cell layer and stellate reticulum-like superficial cells [Table/Fig-4]. Ameloblastomatous epithelium showed intramural plexiform proliferations containing tall columnar basal cells and stellate reticulum-like cells. Prominent vascular components were noted along these plexiform odontogenic proliferations [Table/Fig-5]. The connective tissue stroma was predominantly made up of numerous endothelial lined blood vessels, extravasated Red Blood Cells (RBC) and large blood-filled spaces [Table/Fig-5]. Cystic degeneration was seen in some of the stellate reticulum like areas. Thus, final diagnosis of unicystic ameloblastoma with intramural plexiform hemangiomatous proliferations was given. The patient was treated surgically with a regular follow-up once in six months for two years with no signs of recurrence.

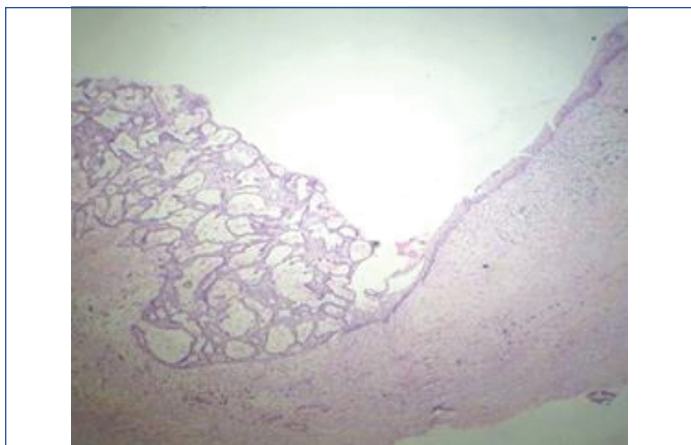
DISCUSSION

The different established histopathological variants of ameloblastoma can exhibit multitude of histopathologic features that may or may not have an impact on the biological behaviour and prognosis of the variant [1,2]. Hemangiomatous ameloblastoma is a solid ameloblastoma of follicular variant showing exuberant proliferation of vascular components including a lot of extravasated RBC and large endothelial lined capillaries [2,3]. Hemangiomatous ameloblastoma

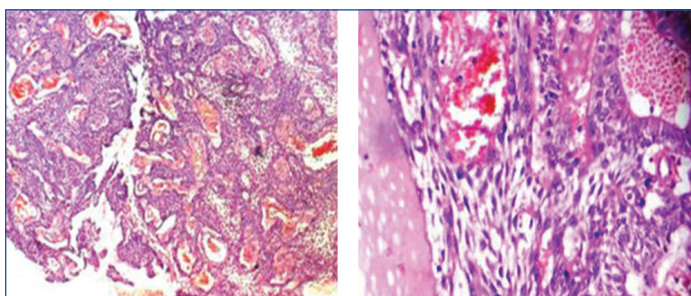


[Table/Fig-1]: Extraoral examination revealing a diffuse swelling involving the left lateral half of the upper lip causing obliteration of the left nasolabial fold. **[Table/Fig-2]:** Intraoral examination showing red solitary, round, soft, fluctuant swelling with focal areas of ulceration, haemorrhage. **[Table/Fig-3]:** IOPAR i.r.t 21, 23, 24, 25 showing radiolucency measuring about 2.5x2 cm in size surrounded by a thin sclerotic border causing divergence of 21,23. (Images from left to right)

occurring in plexiform and unicystic variants of ameloblastoma is rare [1-8]. The literature suggests that the incidence rate of these lesions with such histopathologic features is rare. Only two cases of maxillary premolar- molar region ameloblastoma of hemangiomatous variant has been reported in literature [9,10].



[Table/Fig-4]: Photomicrograph showing cystic lining and underlying connective tissue stroma (H&E stain 4x).



[Table/Fig-5]: Photomicrograph showing odontogenic epithelium with vascular component. (H&E stain, 10x and 40x).

Van Rensburg LJ et al., reported a case with histologic features consistent with those of a unicystic ameloblastoma, but radiologic features and computed tomography suggesting a fibro-osseous lesion and magnetic resonance imaging mimicking a vascular lesion [6]. An unicystic ameloblastoma with intraluminal plexiform hemangiomatous proliferation in an 18-year-old male, an intramural plexiform hemangiomatous proliferation in unicystic ameloblastoma in a 25-year-old male and an intraluminal and intramural plexiform hemangiomatous proliferations in an unicystic ameloblastoma subgroup 1.2.3 in a 24-year-old male patient have been recorded [Table/Fig-6] [3,7,8].

All the reported cases are in males and in the age group of 18 to 25 years and our case too was recorded in the same age and gender category. While most of the reported cases have occurred in the mandibular posterior region associated with an impacted molar [1-8], our case was noted in the maxillary anterior region [9,10]. While our case recorded unilocular radiolucency similar to a case by Dash KC et al., two cases in maxilla showed multilocular radiolucency. Our case histologically was similar to case by Dash KC et al., exhibiting intramural plexiform pattern with hemangiomatous proliferations [8]. Cases with intraluminal as well as intramural hemangiomatous proliferations have been recorded [3,7,8].

Different theories have been postulated to explain the aetiopathogenesis of vascular component in ameloblastoma. Overgrowth of vascular component due to an abnormal induction of the blood supply during amelogenesis, tumour formation by the stimulated epithelial cell rests in periodontal ligament induced by a trauma, such as extraction, development of abnormal vascular component during excessive granulation tissue formation as result of disturbance in the damaged tissue repair, collision tumour, absence of vasoformative activity, secondary changes and repeated surgical interventions are the proposed

Author and year	Age and gender	Site	Radiographic feature	Histological diagnosis
Sarode GS et al., [7]	18 year/ male	Right mandibular posterior	Multilocular radiolucency	Unicystic ameloblastoma with intraluminal plexiform hemangiomatous proliferation
Dash KC et al., [8]	25 year/ male	Left mandibular posterior	Unilocular radiolucency	Unicystic ameloblastoma with intramural plexiform hemangiomatous proliferation
Hegde U et al., [3]	24 year/ male	Left mandibular posterior	Multilocular radiolucency	Unicystic ameloblastoma subgroup 1.2.3 with plexiform hemangiomatous proliferation

[Table/Fig-6]: Cases histologically representing unicystic ameloblastoma with plexiform pattern showing hemangiomatous proliferation.

theories [3-5]. In our case, it might be the secondary changes like ulceration and haemorrhagic spots which have led to the prominent vascular component.

Hemangioameloblastoma by nature is a solid ameloblastoma [11-13]. In our case, it was recorded in a unicystic ameloblastoma. Should this be categorised as unicystic hemangioameloblastoma is yet questionable and rather, can it be considered as a unicystic ameloblastoma with exuberant vascular proliferation. Since, there are very few cases of hemangioameloblastoma being reported and especially in unicystic ameloblastoma; it is not possible to predict its category, nature and prognosis. Only a long-term follow-ups and report of many such cases will throw more light on its behaviour.

CONCLUSION(S)

Vascular lesions of the jaws form an important component of oral pathologies, with few being distinct entities and others being variants of the established pathologies. Though ameloblastoma is common, its histopathological variant hemangioameloblastoma is rare. Hemangiomas proliferations in unicystic ameloblastoma are very rare. Due to the rarity of this lesion, its aetiopathogenesis, clinical features, biological behaviour and prognosis are unknown and cannot be predicted with certainty. The current case would add to the meager literature on hemangiomatous ameloblastoma, particularly in the maxilla.

REFERENCES

- [1] Rajmohan M, Prasad H, Shanmugasundaram N, Thangam PT, Ilayaraja V, Anuthama K. Hemangiomas ameloblastoma: a rare variant. *J Orofac Res*. 2014;4(1):63-66.
- [2] Tamgadje AP, Sirur DG, Bhale Rao SS, Pariera T, Tamgadje SA. Hemangiomas Ameloblastoma: A case report of a rare variant of ameloblastoma. *Int J Contemp Dent*. 2010;2:16-19.
- [3] Hegde U, Sheshanna SH, Chandan SN, Mahima VG. Enriched vascularity in ameloblastomas, an indeterminate entity: Report of two cases. *J Can Res Ther*. 2015;11(4):946-49.
- [4] Kasangari MD, Gundamaraju K, Jyothsna M, Subash AV, Aravind K. Hemangiomas ameloblastoma- a case report of a very rare variant of ameloblastoma. *JCDR*. 2015;9(5):ZD08-ZD10.
- [5] Routray S, Mishra S, Mohanty N, Panda S, Panda P. Recurrent aggressive multicystic ameloblastoma with hemangiomas proliferation and giant cells: A perplexed diagnosis. *Indian J Med Sci*. 2019;71(2):93-96.
- [6] Van Rensburg LJ, Thompson IO, Kruger HE, Norval EJ. Hemangiomas ameloblastoma: Clinical, radiologic, and pathologic features. *Oral Surg Oral Med Oral Pathol Oral Radiol Endod*. 2001;91(3):374-80.
- [7] Sarode GS, Sarode SC, Vaidya K. Intraluminal plexiform hemangiomas ameloblastomatous proliferation in unicystic ameloblastoma: An unusual case report. *Indian J Dent Res*. 2013;24(3):390-92.
- [8] Dash KC, Ramachandra S, Bhuyan L, Kumar H. An insight of intramural plexiform hemangiomas proliferation in unicystic ameloblastoma: A rare case report. *J NTR Univ Health Sci*. 2018;7(3):228-32.
- [9] Sharma VK, Verma SK, Goyal L, Chaudhary PK. Hemangiomas ameloblastoma in maxilla: A report of a very rare case. *Dent Res J*. 2012;9(3):345-49.
- [10] Sachdev SS, Chettiankandy TJ, Sardar MA, Ranganath S, Kharat OD, et al. Hemangiomas Ameloblastoma: A rare variant or secondary change in Ameloblastoma? *J Med Case Rep and Case Series*. 2022;03(03).
- [11] Venigalla A, Bojji M, Piniseti S, Babburi S. Hemangiomas ameloblastoma: Case report with a brief review. *J Oral Maxillofac Pathol*. 2018;22(Suppl 1):S24-S28.

- [12] Childers ELB, Taddasse-Heath L, Bonnick A, Naab T. Vascularized ameloblastoma: A case report and clinicopathologic review of 18 cases from the literature. *Oral Surg Oral Med Oral Pathol Oral Radiol.* 2020;129(6):e264-68.
- [13] Jois HS, Kumar KPM, Kumar MS, Waghrey SA. Mixed neoplasm of intraosseous hemangioma with an ameloblastoma: a case of collision tumor or a rare variant? *Clin Pract.* 2012;2(1):e5.

PARTICULARS OF CONTRIBUTORS:

1. Professor and Head, Department of Oral Medicine and Radiology, JSS Dental College and Hospital, JSS AHER, Mysuru, Karnataka, India.
2. Reader, Department of Oral Medicine and Radiology, JSS Dental College and Hospital, JSS AHER, Mysuru, Karnataka, India.
3. Assistant Professor, Department of Oral Pathology, JSS Dental College and Hospital, JSS AHER, Mysuru, Karnataka, India.
4. Reader, Department of Oral Medicine and Radiology, JSS Dental College and Hospital, JSS AHER, Mysuru, Karnataka, India.
5. Postgraduate Student, Department of Oral Medicine and Radiology, JSS Dental College and Hospital, JSS AHER, Mysuru, Karnataka, India.

NAME, ADDRESS, E-MAIL ID OF THE CORRESPONDING AUTHOR:

Sreeshyla Huchanahalli Sheshanna,
JSSDC&H, JSS AHER SS Nagar Bannim Antap, Mysuru, Karnataka, India.
E-mail: dr.sreeshylahs@jssuni.edu.in

PLAGIARISM CHECKING METHODS: [Jain H et al.]

- Plagiarism X-checker: Nov 25, 2022
- Manual Googling: Jan 06, 2023
- iThenticate Software: Feb 16, 2023 (5%)

ETYMOLOGY: Author Origin**AUTHOR DECLARATION:**

- Financial or Other Competing Interests: None
- Was informed consent obtained from the subjects involved in the study? No
- For any images presented appropriate consent has been obtained from the subjects. Yes

Date of Submission: **Nov 19, 2022**Date of Peer Review: **Jan 05, 2023**Date of Acceptance: **Mar 20, 2023**Date of Publishing: **May 01, 2023**