



Pre Surgical Nasoalveolar Molding (PNAM) to Reduce Cleft Severity in a Nonsyndromic Unilateral Cleft Lip and Palate (UCLP) Patient

Samra Bokhari¹, Iram Bokhari², Irfan Qamaruddin³
and Mohammad Khursheed Alam^{4*}

¹National Institute of Child Health, Karachi, Pakistan.

²Jinnah Post Graduate Medical Center, Karachi, Pakistan.

³Orthodontic Unit, School of Dentistry, Universiti Sains Malaysia, Kota Bharu, Malaysia.

⁴Orthodontic Department, Baqai Medical University, Karachi, Pakistan.

Authors' contributions

This work was carried out in collaboration between all authors. Author SB designed the study and managed the case, wrote the protocol, and wrote the first draft of the manuscript. Author IB wrote checked the manuscript and managed the literature searches. Authors IQ and MKA wrote and checked the manuscript and managed the literature searches. All authors read and approved the final manuscript.

Article Information

DOI: 10.9734/BJMMR/2015/18523

Editor(s):

(1) Ibrahim El-Sayed M. El-Hakim, Ain Shams University, Egypt and Riyadh College of Dentistry and Pharmacy, Riyadh, Saudi Arabia.

Reviewers:

(1) Preeti Tiwari, Oral & Maxillofacial Surgery, IMS, BHU, India.
(2) Man Mahfouz, Orthodontics & Pediatric Dentistry Department, Arab American University Jenin, Palestine.
Complete Peer review History: <http://www.sciencedomain.org/review-history.php?iid=1124&id=12&aid=9654>

Case Study

Received 27th April 2015
Accepted 27th May 2015
Published 8th June 2015

ABSTRACT

Introduction: Pre surgical nasoalveolar molding (PNAM) is a viable option in reducing the severity of the cleft resulting in easier surgical repair and the lip and the nose heal under minimal tension and this leads to less scar formation.

Presentation of Case: A case report with UCLP treated by PNAM appliance is described here.

Discussion: Orthopedic molding reduces the deformity and thus reduces the number of surgeries to achieve superior post-surgical esthetics.

Conclusion: PNAM resulted in well aligned alveolar segments, approximated lip, improved columella-philtrum region and nose.

Keywords: Cleft lip and palate; PNAM; pre surgical infant orthopedic appliance.

1. INTRODUCTION

Cleft lip and palate (CLAP) is one of the most common congenital malformations of the head and neck. In Pakistan the incidence for cleft lip and/or palate was 1.91 per 1000 births. Cleft lip alone (42%), isolated cleft palate (24%) and combined cleft lip and palate (34%). Boys were more commonly affected than girls [1]. It is associated with a large variety of problems like difficulty in feeding, middle ear infections, missing or malformed teeth, nasal speech and the patient is socially compromised [2].

Pre surgical nasoalveolar molding (PNAM) has significantly helped in improving surgical results as it makes the surgical procedure easier by reducing the severity and size of the cleft [3]. Molding was first introduced by McNeil (1950) which helped in reducing the size of the alveolar cleft only [4]. Mylin [5] developed such appliance which was retained by pins. Latham [6] used an invasive appliance which had to be placed surgically. The pioneer of developing the PNAM appliance was Grayson [7] which reduced the alveolar cleft and improved the nose pre-surgically. The effects of presurgical orthopedic plate is effective or not are controversial amongst different treatment providers but a large number of cleft care centers are working on this technique and are providing great results [8-13].

PNAM is a passive non surgical method to approximate the alveolar segments and lips, elongates the columella, and increases the nasal height on the defected side. This is done by using a molding appliance which aids in redirection of arch form. In simple words when the defect has been reduced to a smaller size it would become simpler to operate and would result in less scar tissue and contracture [14].

PNAM should be started as soon as possible after birth. Molding of tissue is much easier in early days of a new born because there is increased level of maternal estrogen and hyaluronic acid in neonates which increases the elasticity of tissues and hence is favorable for molding [15]. Developing nasal cartilage can be subjected to repositioning within the early first six weeks of life and this aid in increasing the nasal height during molding [15].

The concept of the management of cleft lip and palate has changed over the time with more emphasis on the nasal and alveolar molding prior to the primary lip repair. PNAM reduces the number of reconstructive surgeries performed later for the purpose of esthetics [16].

2. CASE PRESENTATION

This new born infant with left sided complete cleft lip and palate was referred from surgical outpatient department for feeding and molding purposes (Fig. 1). Treatment plan was to reduce the severity of the cleft and prepare the patient for an easier surgery. Treatment objectives were to reduce the alveolar segment defect, increase in nasal height and columellar lengthening. Consent was obtained from the parents and treatment was started. Impression tray was custom made from self-cure acrylic with retentive pores for impression material. Impression was taken on the selected impression tray from Heavy bodied Silicon impression material (ORMAPLUS, Italy). Impression was taken by placing the patient upside down by a trained dental nurse. Placing the head in this position helps in keeping the airway open and does not let the secretions go inside. After taking impression the oral cavity is checked for any remaining remnants of impression material. The dentist stands on the right side of the patient for impression taking.

After taking impression the model was poured in stone and the appliance was constructed using heat cured acrylic (BMS, Italy). Steps for fabrication of plate were wax up of the model, flasking and heat curing. Heat cure acrylic was chosen because of its increased strength and less monomer leaching as compared to self-cured acrylic. PNAM appliance was constructed with retentive buttons to aid in extra oral retention. The appliance was checked in the patient's mouth at the age of Day 7. Plate was adjusted in the oral cavity and extra oral retention was taken using Steris strips, orthoelastics, duoderm or tegaderm. The elastics were stretched twice their original strength and the steris placed at an angle of 45° and placed on the temple between the ear and the eye. Mastisol liquid (gum mastisol) adhesive was applied on the Steris and was used to approximate the lip segments (Figs. 2a, b).

After fitting of the tray the patient was recalled on the next day to check for a regular check up to investigate any kind of ulceration due to the appliance and to check proper placement of the appliance by the parents. The patient was recalled for regular weekly checkups for appliance modification. Nasal stents made of self cured acrylic (BMS, Italy) were added on the third appointment when the alveolar cleft was reduced up to 4mm, at that time patient was 1 month old. The nasal stents were covered with a thin veneer of soft acrylic to give soft elastic pressure (Figs. 2c, d). The nasal stent was adjusted every week to get desired shape of the nostril and the alar base.

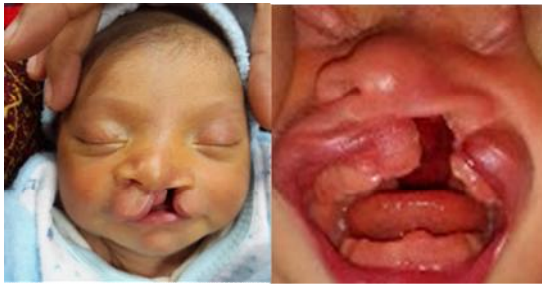

Fig. 1. Left sided complete clefts of the lip, alveolus and palate

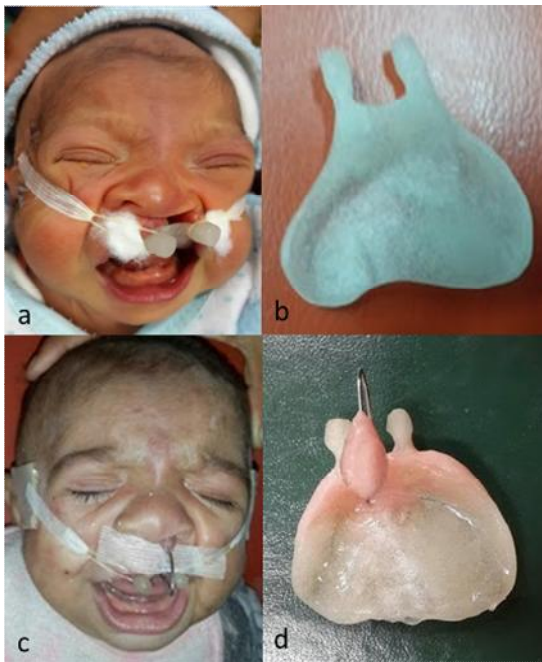

Fig. 2. PNAM appliance in the children's oral cavity: a. extraoral view, b. PNAM appliance, c. extraoral view after addition of nasal stents and d. PNAM appliance with nasal stents

The alveolar intersegment defect through PNAM was reduced from 6 mm to 0 mm, nasal height was increased from 0 mm to 5 mm and columella was increased from 3 mm to 5 mm (Fig. 3). Average palatal width was 36 mm in pretreatment and 37 mm in post NAM. The measurements were taken by only one trained orthodontist to avoid ambiguity in data collection.

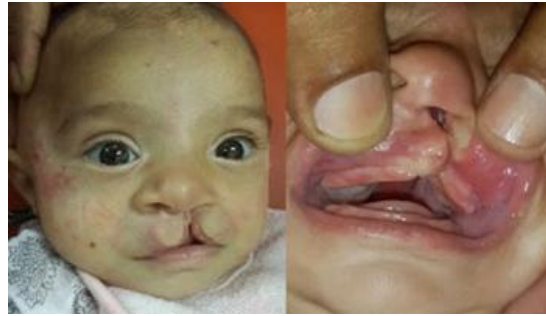

Fig. 3. After PNAM treatment, size of the alveolar cleft reduced, nasal height and columella height increased

The patient was sent for lip repair after the desired results of reduction of alveolar cleft size, increase in nasal height and columellar lengthening through PNAM were achieved. All procedures were carried out at National institute of Child health, Karachi, Pakistan from March 2014 to June 2014 by a calibrated and well trained orthodontist. The patient was sent for lip repair after the desired results of PNAM were achieved. Lip surgery was done by a well-known plastic surgeon working under smile train. Fig. 4 shows extra oral views after lip repair. Fig. 5 shows 1 year follow-up extra oral views. Fig. 6 shows prospective changes in alveolar cleft indicated by an arrow.

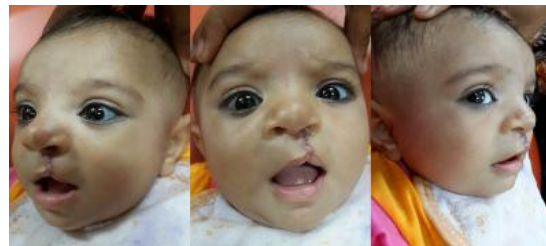

Fig. 4. Extraoral views after lip repair

3. DISCUSSION

PNAM is an extremely reliable method for treatment of CLAP patients prior to surgery [17]. It saves the patients from multiple surgeries and

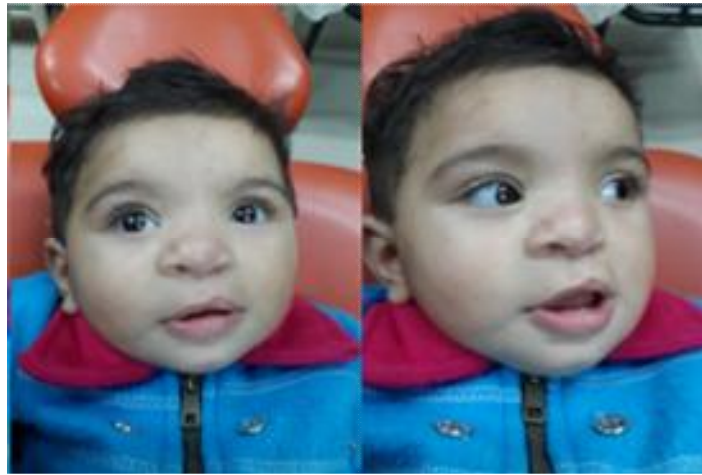

Fig. 5. Extraoral views after 1 year follow-up

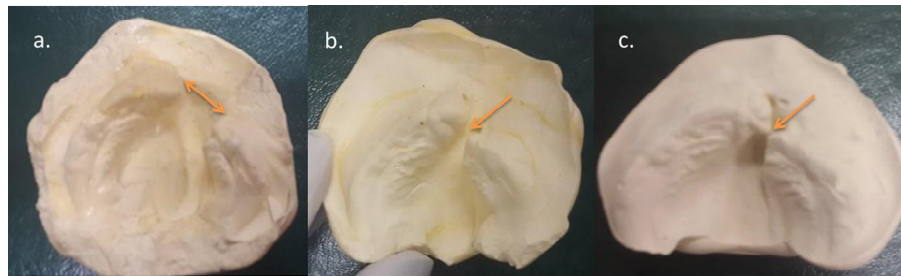


Fig. 6. Model photographs, a. initial, b. after PNAM treatment and c. after 1 year follow-up

alveolar bone grafting, nasal stents attached to the alveolar molding appliance, yield significant improvement of the nasal morphology and better nasal aesthetics presurgically and hence reduces the cost of the overall treatment [16]. It immensely satisfies the mental stress of the parents of the child. PNAM appliance has multiple benefits; it serves as a feeding plate, approximates the alveolar segments and the lips, and also elevates the nostrils. Patients treated with PNAM have better surgical outcomes and less scarring as compared to untreated cases [18]. Different surgical techniques [19,20] may result in different treatment outcomes in a CLAP patients. Indices to determine the treatment outcome results also varies [21]. Later, CLAP patients suffers with different dental anomalies [22]. A multifactorial etiology and verities of gene involvements [23] maybe one of the potential reason.

Extreme degree of compliance is required by the parents for weekly visits to the outpatient department for appliance modification and for daily strapping and tapping of the patient. In case

of ulceration, trauma or breakage of the appliance the parent should immediately report to the dental clinic. Meticulous cleanliness of the face, the appliance and the oral cavity is required to prevent any kind of infection. PNAM should be started within the first few weeks after birth, as the infant grows the modifiability of the tissue and the bone reduces [7].

Complications can be seen as non compliance by the parents, ulcerations due to the appliance or elastics, breakage of appliance, swallowing of appliance and allergies [2].

Not all infants born with cleft have to be treated in the same manner. Each individual has his/her own tolerances and medical conditions. The technique has to be modified according to the patient's needs.

4. CONCLUSION

Alveolar and nasal surgeries are always challenging for reconstructive surgeons. PNAM reduces the severity of the cleft and hence it is

easier for the surgeon to correct the defect. A simpler surgery would result in less scarring and less tissue tension which in the long run would reduce the undesirable effects on growth. In an under developed country like Pakistan with the high prevalence of cleft lip and palate, PNAM can be a viable option. It improves the surgical outcome and lessens the number of surgeries, which not only results in better esthetics but also reduces the cost of treatment.

CONSENT

All authors declare that 'written informed consent was obtained from the patient (or other approved parties) for publication of this case report and accompanying images.

COMPETING INTERESTS

Authors have declared that no competing interests exist.

REFERENCES

1. Elahi MM, Jackson IT, Elahi O, Khan AH, Mubarak F, Tariq GB, Mitra A. Epidemiology of cleft lip and cleft palate in Pakistan. *Plast Reconstr Surg.* 2004; 113(6):1548-55.
2. Akshai SKR, Krishnamurthy B, Dharma RM, Viswapurna PS. Pre-surgical nasoalveolar molding in patients with unilateral clefts of lip, alveolus and palate - a case report. *Annals Essenc Dent.* 2011; 3(2):50.
3. Radhakrishnan V, Sabarinath VP, Thombare P, Hazarey PV, Bonde R, Sheorain A. Presurgical nasoalveolar molding assisted primary reconstruction in complete unilateral cleft lip palate infants. *J Clin Pediatr Dent.* 2010;34:267-74.
4. McNiel C. Orthodontic procedures in the treatment of congenital cleft palate. *Dent Rec.* 1950;70:126-32.
5. Mylin W. The pin-retained prosthesis in cleft palate orthodontics. *Cleft Palate J.* 1968;5:219-24.
6. Latham R. Orthodontic advancement of the cleft maxillary segment: A Preliminary Report *Cleft Palate J.* 1980;227-33.
7. Grayson BH, Shetye PR. Presurgical nasoalveolar molding treatment in cleft lip and cleft palate. *Indian J Plast Surg Suppl.* 2009;42:56-61.
8. Hotz MM, Gnoinski WM. Effects of early maxillary orthopaedics in coordination with delayed surgery for cleft lip and palate. *J Maxillofac Surg.* 1979;7:201-10.
9. Alam MK, Kajii TS, Koshikawa-Matsuno M, Sugawara-Kato Y, Sato Y, Iida J. Multivariate analysis of factors affecting dental arch relationships in Japanese unilateral cleft lip and palate patients at Hokkaido University Hospital. *Orthod Waves.* 2008;67:45-53.
10. Bongaarts CAM, van't Hof MA, Prahlandersen B, Dirks IV, Kuijpers-Jagtman AM. Infant orthopedics has no effect on maxillary arch dimensions in the deciduous dentition of children with complete unilateral cleft lip and palate (Dutchcleft). *Cleft Palate Craniofac J.* 2006;43:665-72.
11. Kajii TS, Alam MK, Mikoya T, Oyama A, Koshikawa-Matsuno M, Sugawara-Kato Y, Sato Y, Iida J. Congenital and postnatal factors inducing malocclusions in Japanese unilateral cleft lip and palate patients - determination using logistic regression analysis. *The Cleft Palate-Craniofacial Journal.* 2013;50(4):466-472.
12. Alam MK, Iida J, Sato Y, Kajii TS. Postnatal treatment factors affecting craniofacial morphology of unilateral cleft lip and palate (UCLP) patients in a Japanese population. *Br J Oral Maxillofac Surg.* 2013;51(8):e205-10.
13. Mino Koshikawa-Matsuno, Kajii TS, Alam MK, Sugawara-Kato Y, Iida J. The effects of palatoplasty and pre-surgical infant orthopedic treatment on occlusion in unilateral cleft lip and palate patients. *Orthod Waves.* 2014;73:114-120.
14. Yang S, Stelnicki EJ, Lee MN. Use of nasoalveolar molding appliance to direct growth in newborn patient with complete unilateral cleft lip and palate. *Pediatr Dent.* 2003; 25(3):253-6.
15. Matsuo K, Hirose T. Non surgical correction of congenital auricular deformities in early neonates, a preliminary report. *Plast Reconstr Surg.* 1984;73:38-50.
16. Murthy PS, Deshmukh S, Bhagyalakshmi A, Srilatha K. Presurgical nasoalveolar molding: Changing paradigms in early cleft lip and palate rehabilitation. *J Int Oral Health.* 2013;5(2):70-80.
17. Punga R, Sharma SM. Presurgical orthopaedic nasoalveolar molding in cleft lip and palate infants: A comparative evaluation of cases done with and without

- nasal stents. J Maxillofac Oral Surg. 2013; 12(3):273-88.
18. Grayson BH, Maull D. Nasoalveolar Molding for Infants Born with Clefts of the Lip, Alveolus, and Palate. Semin Plast Surg. 2005;19(4):294–301.
 19. Haque S, Alam MK. Spectrum of cheiloplasty has detrimental effect on maxillary growth: myth or fact? Bangladesh J Med Sci. 2014;13(4):473-476.
 20. Haque S, Alam MK. Spectrum of palatoplasty has detrimental effect on maxillary growth: myth or fact? Bangladesh J Med Sci. 2015;14(1):109-110.
 21. Haque S, Alam MK, Arshad AI. An Overview of Indices Used to Measure Treatment Effectiveness in Patients with Cleft Lip and Palate. Malaysian J Med Sci. 2015;22(1):4-11.
 22. Haque S, Alam MK. Common dental anomalies in cleft lip and palate patients. Malaysian J Med Sci. 2015;22(2):55-60.
 23. Haque S, Alam MK. Gene involvement in cleft lip and palate (CLP) patients. Bangladesh J Med Sci. 2015;14(1):113-116.

© 2015 Bokhari et al.; This is an Open Access article distributed under the terms of the Creative Commons Attribution License (<http://creativecommons.org/licenses/by/4.0>), which permits unrestricted use, distribution, and reproduction in any medium, provided the original work is properly cited.

Peer-review history:

The peer review history for this paper can be accessed here:
<http://www.sciencedomain.org/review-history.php?iid=1124&id=12&aid=9654>