



## Gingival Depigmentation by Cryosurgery and Laser Application - A Comparative Clinical Study

Ponaganti Venkata Narsimha Rao<sup>1</sup>, Gautami S. Penmetsa<sup>1\*</sup>  
and C. D. Dwarakanath<sup>1</sup>

<sup>1</sup>Department of Periodontics and Implantology, Vishnu Dental College, Bhimavaram, Andhra Pradesh, India.

### Authors' contributions

This work was carried out in collaboration between all authors. Author CDD designed the study, wrote the protocol, and wrote the first draft of the manuscript. Author GSP managed the literature searches, analyses of the study and author PVNR managed the experimental process. All authors read and approved the final manuscript.

### Article Information

DOI: 10.9734/BJMMR/2015/12870

#### Editor(s):

(1) Li (Peter) Mei, Faculty of Dentistry, Discipline of Orthodontics, University of Otago, New Zealand.

#### Reviewers:

(1) Anonymous, Maharashtra University of Health Sciences, India.

(2) Anonymous, Federal University of Rio Grande do Sul, Brazil.

Complete Peer review History: <http://www.sciencedomain.org/review-history.php?iid=718&id=12&aid=6955>

Original Research Article

Received 22<sup>nd</sup> July 2014  
Accepted 23<sup>rd</sup> October 2014  
Published 15<sup>th</sup> November 2014

### ABSTRACT

**Aims:** The main aim of this study was to compare the efficacy of laser over cryosurgery and to evaluate the intensity of repigmentation after both interventions during a period of 9 months."

**Study Design:** This study was a randomized controlled clinical split mouth trial.

**Place and Duration of Study:** Department of Periodontics, Vishnu Dental College and hospital between January 2013 to September 2013.

**Methodology:** Sample we included 20 subjects (10 males, 10 females) age range 19-23 years with hyper pigmented gingiva on facial aspect of the gingiva present in the esthetic zone. A split mouth approach was used wherein one side received laser and the other side received cryotherapy with the choice of the therapy and side chosen by the spin of the coin. Clinical observations for intensity of pigmentation were recorded at baseline, 3, 6 and 9 months after surgery.

**Results:** With a sample of 20 patients the treatment of gingival hyperpigmentation with laser and cryosurgery showed marked improvement of gingival pigmentation in both the groups. When intergroup comparison was made there was no statistical difference in the score from baseline (P-value, 1.0000). However there was statistical improvement that was significant in cryosurgery

\*Corresponding author: Email: [gautamipenmetsa@gmail.com](mailto:gautamipenmetsa@gmail.com);

group as compared to laser group at the end of 9<sup>th</sup> month (P-value, 0.0020). Moreover 6 out of 20 patients were satisfied with the laser treated at the end of 9 months whereas 18 patients (90%) reported excellent appearance in cryosurgery group at the end of 9 months (P-value, 0.00001).

**Conclusion:** The indications of recurrence in laser treated group were early compared to the cryo treated group which showed more sustainability over the entire study period

*Keywords: Melanin depigmentation; depigmentation; laser; cryosurgery.*

## 1. INTRODUCTION

Facial and dental esthetics play an important role in a person's life being the strong determinants for the upliftment of morale and confidence. In the recent times, periodontal esthetics has been considered to play a major role in the overall esthetic program because the harmony of a smile is determined not only by shape, position, color of teeth but also by the color and dimensions of the gingiva [1]. Various esthetic problems affecting gingiva include gingival recession, gingival asymmetry, gingival overgrowth, incomplete passive eruption, and gingival hyperpigmentation.

Hyperpigmentation of gingiva which occurs due to excessive production of melanin is usually physiological and does not present a medical problem [2]. However; many patients consider their black or brownish gums to be unesthetic contributing to an unpleasing smile [2,3]. The periodontist has a vital role to play in contributing to the enhancement of patient's overall esthetics by gingival depigmentation which has become an integral part of periodontal plastic procedures [2].

Gingival hyperpigmentation which is seen as a genetic trait in some populations irrespective of age and gender, is termed as physiologic pigmentation. Thus degree of pigmentation varies from one individual to another depending upon the melanoblastic activity. Gingival hyperpigmentation can be localized or generalized [4] which is caused by excessive melanin deposition by the melanocytes mainly located in the basal and suprabasal cell layers of the epithelium [5].

The treatment for gingival depigmentation has many different techniques in vogue which include gingivectomy, mucosal excision by scalpel, abrasion technique, free gingival grafts, chemical methods using escharotic agents, electrosurgery, cryosurgery and more lately lasers [6,7].

Mucosal excision with scalpel, performed usually with a number 11 BP blade has been a standard

procedure, where in the superficial overlying epithelium is removed leaving a raw bleeding surface which is protected by a periodontal dressing, until healing takes place by secondary intention. Although this is a fairly predictive procedure, it suffers from various drawbacks such as technique sensitivity, requirement of local anesthesia, bleeding, post operative pain etc., [8].

The requisites for an ideal treatment modality include minimum discomfort to the patient, minimal or no anesthesia, operator friendliness, less technique sensitivity, minimal or no bleeding during surgery, controlled destruction of the tissues, minimum postoperative complications and finally a pleasing outcome sustaining over a long period of time. Cryosurgery and off late lasers have several above mentioned advantages such as minimum discomfort to the patient, minimal or no anesthesia, operator friendliness, minimal swelling, technically less sensitive, high patient acceptance and less post operative pain [2].

Although there are several reports of using lasers for different periodontal applications including gingival depigmentation, they suffer from the major drawback of being expensive and different laser systems being required for various applications. Cryosurgical applications on the other hand could offer a simple, economically viable alternative because they are relatively inexpensive, easy to handle and do not require the strict protocol as required for laser application [7].

However, no study till date has compared these two modalities in the treatment of gingival pigmentation. Hence this study envisages to compare cryosurgery with laser application in the depigmentation of the gingiva.

## 2. METHODS AND MATERIALS

### 2.1 Patient Sample

In this randomized controlled split-mouth clinical study, subjects from both genders, aged between

18-30 years old, and with an esthetic complaint of hyperpigmented gingiva on the facial aspect of the teeth present in the esthetic zone were chosen from those visiting the Department of Periodontics, Vishnu Dental College, Bhimavaram. The sample size comprehending 20 patients was calculated based on the findings of a pilot study and using an 80% power (standard deviation= 0.2, mean= 1.8, error to be expected= 10%of mean). All the patients were briefed about the proposed surgical procedure in detail, including the anticipated outcome and an informed consent was obtained. The study was scheduled from January 2013 to September 2013 over a period of 9 months.

The enrollment of 20 patients was based on the inclusion criteria with:

- 1) Patients aware of the nature of physiological hyperpigmentation of their gums and who requested for improvement of their gingival appearance.
- 2) Patients with the presence of moderate to severe physiological melanin pigmentation of the gingiva in the anterior region.

Patients were excluded based on the following criteria

- 1) Patients with systemic diseases that can interfere with healing and medically compromised conditions.
- 2) Pregnancy.
- 3) History of post surgical keloids.
- 4) Smoking.
- 5) Acute gingival and periodontal diseases.
- 6) Pathologically pigmented lesions of gingiva.
- 7) Subjects showing extremely thin gingiva and gingival recession.

A specially designed Proforma for this study was used to record all the details which included the following parameters:

Plaque index (silness.P and Loe.H 1964)  
Gingival index (Loe.H and Silness.P 1963)  
Gingival bleeding index (Ainamo J and Bay I 1975)  
Oral pigmentation index (Dummett C.O 1964)  
Esthetic appraisal by the patient.

After obtaining a detailed medical history to rule out any pathological oral pigmentation, the selected subjects were provided routine oral

prophylaxis and plaque control instructions to ensure disease free gingiva. Depending upon the smile line, mouth opening in the normal smile position and the visibility of the teeth, the surgical area in maxilla, mandible or both were demarcated. A split mouth approach was used by randomly assigning one side of the mouth to receive laser therapy and the other side to receive cryotherapy based on the spin of the coin. For each patient, laser therapy was performed first followed by cryosurgery and patients were followed at 1 month, 3 months, 6 months and after 9 months.

## 2.2 Surgical Procedure

### 2.2.1 Laser procedure

After performing the presurgical chlorhexidine rinse (0.2%), an anesthetic (Xynova™) gel of lignocaine hydrochloride 2% was applied on to the surgical site.

The laser equipment used in this study is a semiconductor diode laser (Ga, Al, As) manufactured by FONA™ (Fig. 1), with a wavelength of  $970\pm 15\text{nm}$ , and operatory modes were of Continuous wave, Chopped mode and peak pulse mode. The power range was of 0.5-4W and peak pulse 7W with a frequency of 1Hz-100Hz with dimensions of  $19.7\times 18.2\times 18.9\text{ cm}$ .

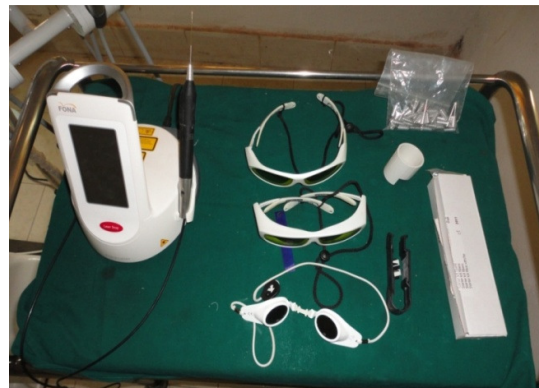

Fig. 1. Laser unit

In this study the power setting of 3W with a constant power of 2W was employed intermittently at 35 seconds. A sweeping brush technique in a contact pulsed mode was employed till the gingival surface is completely free of pigmentation. Care was taken to move the fiber tip continuously across the site to avoid heat accumulation at one site and not to produce excessive charring.

### **2.2.2 Cryosurgical procedure**

The cryosurgical apparatus used was cryo super deluxe model no 004-B manufactured by (Basco Cryos company) (Figs. 2 and 3), this works on the Joule-Thomson principle using nitrous oxide gas at a temperature of -70 to -80°C at the probe tip. After the laser application was completed cryosurgery was performed in the same sitting. Cryosurgery was performed with the probe tip placed on the surgical area with a derm probe pointing towards the interdental area. After the freezing began, the probe tip adheres to the tissues forming visible snow white ice ball. After 10 seconds the piston trigger was released and the probe along with the tissues were allowed to thaw sufficiently before removal. The entire surgical area were frozen in concentric circles following which a repeated cycle of application was done for another 10 seconds to ensure gingiva completely free of pigmentation.



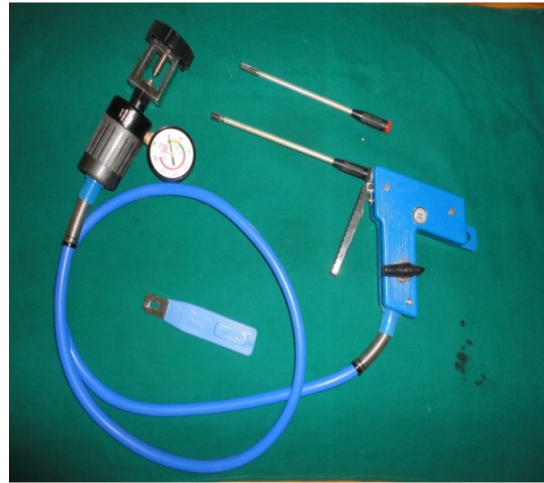
**Fig. 2. Cryosurgical unit**

### **2.2.3 Post operative care**

All the patients along with routine periodontal instructions were asked to refrain from brushing on the surgical site for a period of 3 days after which they were asked to gently brush with a soft tooth brush.

### **2.3 Estimation of Pain Intensity Following Surgery**

All patients were asked to define their pain level by using visual analog scale (VAS) which was assessed at one week after the procedure. VAS consists of equal units from 0 to 10, score 0 was presented as no pain, score 1-3 as slight pain, score 4-6 as moderate pain and score 7-10 as severe pain.



**Fig. 3. Piston trigger with probe tips**

### **2.4 Esthetic Appraisal**

The specially designed pro-forma also included a simple questionnaire assessing the esthetic appraisal of the patient at the end of study period.

### **2.5 Statistical Analysis Carried Out**

The Mann-Whitney U test was used to determine the possible intergroup differences 1.3.6 and 9 months postoperatively. The Wilcoxon signed-rank test was used to analyze if the clinical parameters were different between intervals of time (intragroup differences: baseline-1 month, baseline-3 months, baseline -6 months, baseline-9 months).

## **3. RESULTS**

A Total of 23 subjects with the complaint of unpleasing gums who needed gingival depigmentation were initially included in the present clinical study. However, as 3 patients could not be evaluated as they migrated out of the country, the final sample comprised of 20 patients, with the age ranging from 19-23 years, being 10 males and 10 females."

### **3.1 Periodontal Variables**

The plaque score at baseline being  $0.79 \pm 0.51$  decreased to  $0.43 \pm 0.42$  at 1<sup>st</sup> month which gradually reduced to  $0.19 \pm 0.31$  at the end of 9 months. Gingival score at baseline being  $0.61 \pm 0.52$  decreased to  $0.44 \pm 0.36$  at 1<sup>st</sup> month which gradually reduced to  $0.13 \pm 0.24$  at the end

of 9 months. The gingival bleeding index baseline score of  $0.0 \pm 0.0$  till 9<sup>th</sup> month of score  $0.0 \pm 0.0$  was seen throughout the entire period of study with a constant reinforcement of oral hygiene Table 1.

### 3.2 Pain Score

Pain score was  $1.3 \pm 2$  in laser group and  $1.8 \pm 1.7$  in the cryosurgery group with no statistically significant difference between the two. ( $p=1.000$ ) Table 2. However none of the patients complained of major discomfort during the procedure in both the groups; with no patients requesting administration of local anesthesia.

### 3.3 Pigmentation Score

The mean value of the pigmentation score in laser group was  $2.2 \pm 0.4$  at baseline which reduced to  $0.0 \pm 0.0$  at one month. However this score changed to  $0.9 \pm 0.6$  at the end of 3<sup>rd</sup> month ending up to at  $1.4 \pm 0.9$  at the end of 9 months; with a trend towards to recurrence of pigmentation from 3<sup>rd</sup> month onwards, even though the scores still were significantly lower than the baseline scores. In cryosurgery group the mean pigmentation score was  $2.2 \pm 0.4$  reducing to 0 at 1 month and the same was maintained throughout the study period till the end of 9<sup>th</sup> month with no clinically expressive recurrence being observed, and this difference of score from baseline to 1, 3, 6 and 9 months were statistically significant" Table 3.

In the inter comparison group, there was statistical significant improvement in cryosurgery group as compared to laser group from 3<sup>rd</sup> month onwards. ( $p=0.002$ ) Table 4.

### 3.4 Esthetic Appraisal

14 out of 20 patients were unsatisfied at the end of 9 months with the laser treated area whereas 18 patients (90%) reported excellent appearance in cryosurgery group at the end of 9 months Table 5.

## 4. DISCUSSION

The increase demand for optimal esthetics by dental patients has led to various periodontal plastic and cosmetic procedures being practiced by the clinicians in the recent times.

Management of hyperpigmented gums is one such procedure in the repertoire of the periodontist. Esthetically patients who were unsatisfied with the colour of the gingiva and the associated smile were included in the study.

Mucosal excisions by scalpel, cryosurgery and laser surgery have been the methods frequently employed in the last decade to achieve gingival depigmentation amongst which Cryosurgery, which employs tissue destruction by freezing, has become a firmly established surgical technique in dental practice [2]. The cryosurgical system used in this study utilized the Joule-Thomson technique wherein nitrous oxide gas was used to produce a temperature of  $-60$  to  $-70^\circ\text{C}$  at the tip of a specially designed probe [2]. All the cases showed complete elimination of gingival pigmentation and the resultant outcome was esthetically highly acceptable and was maintained during the entire 9 months of study period Figs. 4 and 5.

Similar results have been reported by Shaeesta Khaleel Ahmed et al. [7] wherein depigmentation was performed on 21 female patients with the freezing agent used being nitrous oxide gas. The patients reported no adverse effects with no repigmentation evident in the treated areas for a period of 30 months.

Investigators also performed the gingival depigmentation procedure on 20 patients by direct application of liquid nitrogen with a cotton swab for 20 to 30 seconds; with no evidence of repigmentation in any of the subjects after a period of 6 months and the acceptance of the treatment was excellent [9].

A major surprising and unexpected finding of this study was the rapid recurrence of pigmentation in the areas treated by laser. Whereas, depigmentation was complete and excellent at the first month, isolated spots of pigmented areas started appearing from the 3<sup>rd</sup> month onwards, which intensified by the end of 9 months. Whatever the grade of repigmentation that occurred, appeared to complete by 6 months which remained constant for the next 3 months. This finding is in contrast to the reports published earlier in several studies wherein recurrence was not observed for a duration of anywhere from 18 to 30 months [10].

**Table 1. Comparison of different time points with plaque index scores**

Time points	Plaque index			Gingival index			Gingival bleeding index		
	Mean	Std.Dv.	P-value	Mean	Std.Dv.	P-value	Mean	Std.Dv.	P-value
Baseline	0.79	0.51	0.000*	0.61	0.52	0.001*	0.00	0.00	NS
1 month	0.43	0.42		0.44	0.36		0.00	0.00	
Baseline	0.79	0.51		0.61	0.52	0.001*	0.00	0.00	NS
3rd month	0.30	0.42	0.003*	0.20	0.25		0.00	0.00	
Baseline	0.79	0.51		0.61	0.52	0.001*	0.00	0.00	NS
6th month	0.21	0.32	0.000*	0.16	0.29		0.00	0.00	
Baseline	0.79	0.51		0.61	0.52	0.002*	0.00	0.00	
9th month	0.19	0.31	0.000*	0.13	0.24		0.00	0.00	NS

\*p=0.05- statistically significant  
NS= Not significant

**Table 2. Comparison of group I (Laser group) and group II (Cryosurgery group) with respect to pain scores at immediate treatment, 1 day and by 1 week after surgery**

Time	Group	Mean	SD	P-value
Immediate	Group I	1.3	2.0	0.185
	Group II	1.8	1.7	
1 day after	Group I	0.0	0.0	0.058
	Group II	0.5	0.7	
1 week after	Group I	0.0	0.0	1.000
	Group II	0.0	0.0	

**Table 3. Comparison of baseline, 1 month, 3 months, 6 months and 9 months with respect to pigmentation scores in group I and group II**

Time points	Group I			Group II		
	Mean	Std.Dv.	P-value	Mean	Std.Dv.	P-value
Baseline	2.2	0.4		2.2	0.4	
1 month	0.0	0.0	0.000*	0.0	0.0	0.000*
Baseline	2.2	0.4		2.2	0.4	
3 months	0.9	0.6	0.000*	0.1	0.3	0.000*
Baseline	2.2	0.4		2.2	0.4	
6 months	1.5	0.6	0.003*	0.4	0.8	0.000*
Baseline	2.2	0.4		2.2	0.4	
9 months	1.4	0.9	0.011*	0.4	0.5	0.000*

**Table 4. Comparison of group I (Laser group) and group II (Cryosurgery group) with respect to pigmentation scores at changes from baseline to 1 month, baseline to 3 months, baseline to 6 months and baseline to 9 months**

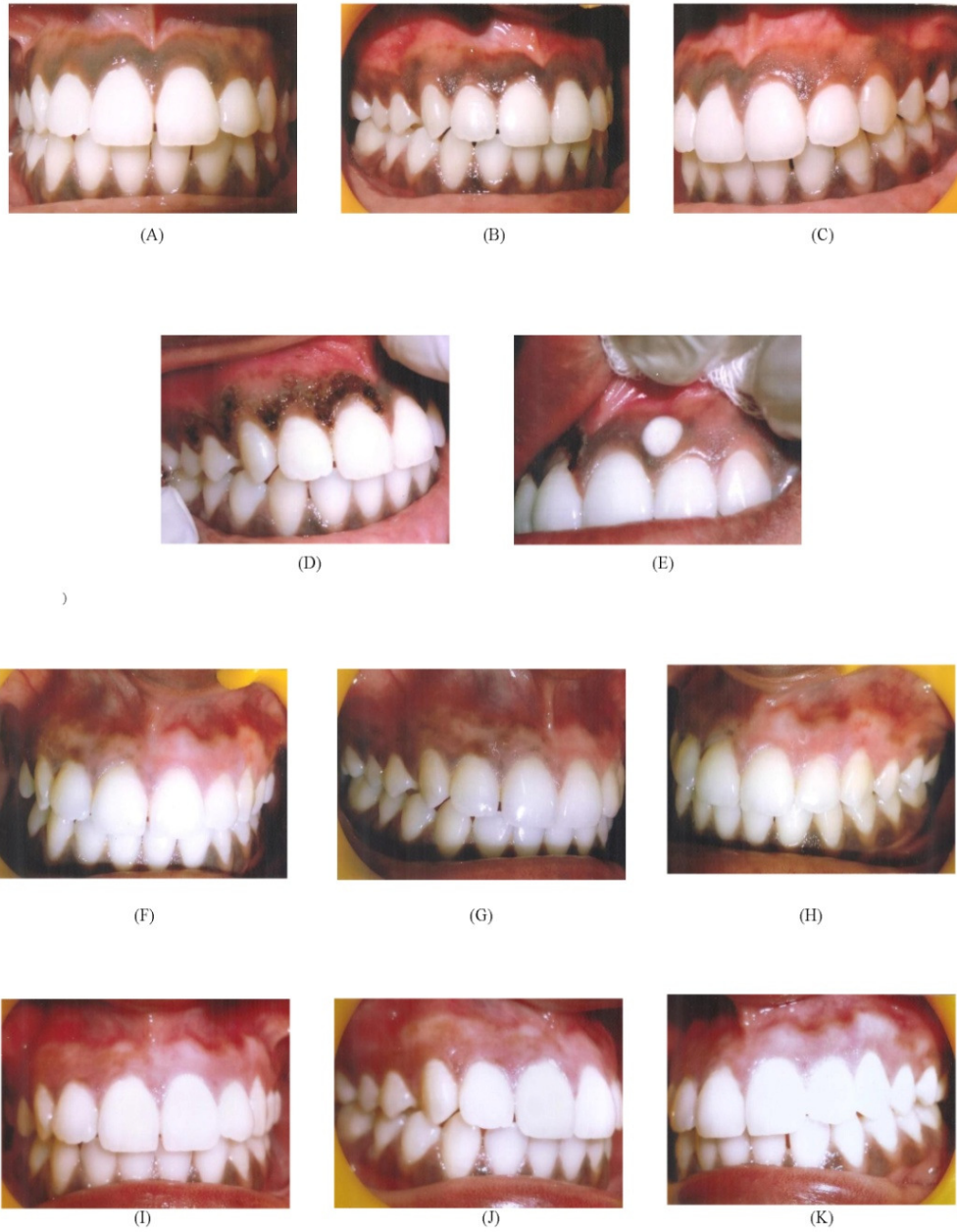Time	Group	Mean	SD	P-value
BL-1M	Group I	2.2	0.4	1.000
	Group II	2.2	0.4	
BL-3M	Group I	1.3	0.6	0.000*
	Group II	2.1	0.5	
BL-6M	Group I	0.7	0.7	0.000*
	Group II	1.8	0.6	
BL-9M	Group I	0.8	1.1	0.002*
	Group II	1.8	0.6	



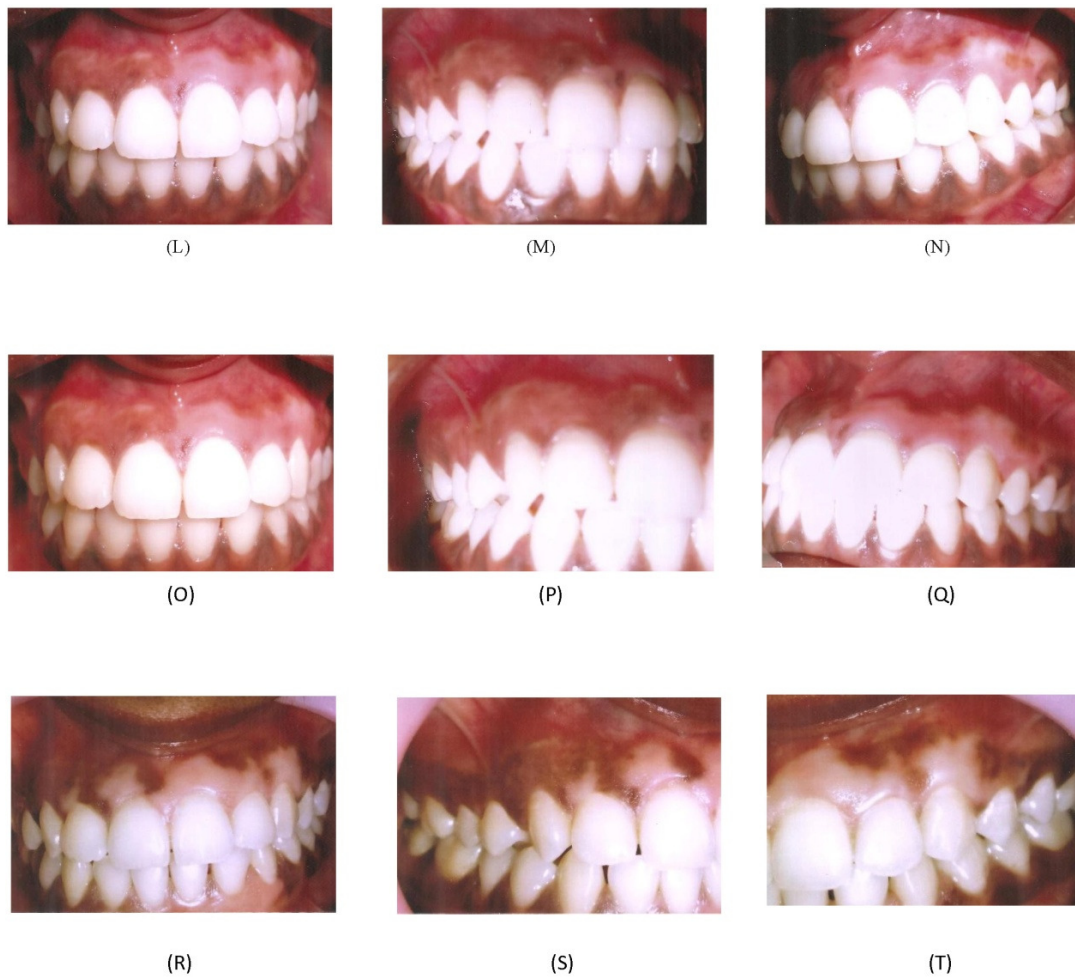**Table 5. Comparison of group I (Laser group) and group II (Cryosurgery group) with respect to esthetic appraisal**

Aesthetic appraisal	Group I	%	Group II	%	Total	%
Excellent	0	0.0	18	90.0	18	45.0
Satisfactory	6	30.0	2	10.0	8	20.0
Unsatisfactory	14	70.0	0	0.0	14	35.0
Total	20	100.0	20	100.0	40	100.0

Chi-square= 34.0010, P = 0.000\*



**Fig. 4. Clinical figures of one patient undergone laser and cryosurgical depigmentation procedure for the period of 9 months**



A) Preoperative picture of frontal view with grade 3 Oral pigmentation index (Dummett C.O Gupta), B) Preoperative picture of right lateral view, C) Preoperative picture of left lateral view, D) During treatment with laser therapy, E) During treatment with cryosurgery, F) Immediate post operative picture of frontal view after 2 weeks, G) Immediate post operative picture of right lateral view, H) Immediate post operative picture of lateral lateral view, I) One month post operative picture of frontal view, J) One month post operative picture of right lateral view, K) One month post operative picture of left lateral view, L) Three months post operative picture of frontal view, M) Three months post operative picture of left lateral view, N) Three months post operative picture of right lateral view, O) Six months post operative picture of frontal view, P) Six months post operative picture of right lateral view, Q) Six months post operative picture of left lateral view, R) Nine months post operative picture of frontal view, S) Nine months post operative picture of right lateral view, T) Nine months post operative picture of left lateral view

**Fig. 5. Complete evaluation of a treated case depicting various stages of treatment (Pre-operative to post-operative up to 9 months)**

Studies by authors in which diode lasers were employed with a wavelength of 980nm, power of 2-4W, pulse intervals varying from 20 and 50 milliseconds no repigmentation was observed after 15 months and 1 year follow-ups [11].

However in another study with the above laser configurations, no repigmentation was observed after 3 years follow up [12].

A study conducted on depigmentation procedure, used CO<sub>2</sub> laser with power of 6-8W and pulse

duration of 0.2 seconds, four of seven cases showed repigmentation at 24 months follow up period [13].

The diode laser used in this study employed has a wavelength of 970±15nm, and operatory modes were of continuous wave, chopped mode and peak pulse mode with a power range of 0.5-4W and peak pulse 7W with a frequency of 1Hz-100Hz. All the cases were treated by a power setting of 3.5W, frequency 3Hz, energy 52.1J,



average power 2W, time 35 sec, and duty cycle 50%.

Even though the manufacturer's instructions were strictly followed and all other factors under control, if still an early recurrence was observed, one of the reasons given for early recurrence for gingival depigmentation is the color of skin of the patient [14]. It has been hypothesized that dark skinned individuals show earlier recurrence as compared to light skinned people [15,16]. However, that reasoning cannot be accepted here as there was no recurrence in whatsoever in the sites treated by cryosurgery. Hence, it has to be surmised that laser equipment FONA™ that was used here might have not performed as has been as per the specifications that came along with it. Better understanding of the laser system, choice of a better laser being tried in more number of cases with longer follow up may throw further light into the aspect. However the physiology of melanocytes and the activity of the melanocytes both at a cellular and molecular level need to be researched and investigated in detail. Regarding the esthetic appraisal of the patients 6 out of 20 patients were satisfied with laser treated areas and 18 patients reported excellent esthetics in the cryosurgery group at the end of the study period.

## 5. CONCLUSION

Initially both the treatments responded very well. But on follow up, patients with laser started showing recurrence of pigments from 3<sup>rd</sup> month onwards. However, results of cryosurgery were stable even upto 9 months. Hence it is concluded that cryosurgical treatment offered consistent and superior results compared to laser.

## CONSENT

The patients who participated in this study gave their informed consent and variously counseled by the researchers and their consents were obtained before they were enrolled in the study. Moreover, counseling was done at every stage of research.

## ETHICAL APPROVAL

Ethical approval was obtained from the hospital's ethical committee before the commencement of the study. The study was performed in accordance with ethical standards laid down in the standard operating procedures (SOPs) for institutional ethics committee (IEC) of ICMR'S - New Delhi.

## COMPETING INTERESTS

Authors have declared that no competing interests exist.

## REFERENCES

1. Anuradha GB, Japati S. Black to pink: clinical evaluation of two different surgical approaches for the treatment of hyperpigmentation. *Int J Prosthodont Res Dent.* 2011;1:136-139.
2. Tal H, Landsberg J, Kozlovsky A. Cryosurgical depigmentation of the gingiva - A case report. *J Clin Periodontol.* 1987;14:614-617.
3. Shah SS. Surgical esthetic correction for gingival pigmentation: Case series. *Journal of Interdisciplinary Dentistry.* 2012;2:195-200.
4. Kumar M, Bandyopadhyay P, Kundu D, Mishra L. Cryosurgery by tetrafluoroethane: An answer to black gums. *J Ind Soc Periodontol.* 2013;17:257-260.
5. Atsawasuwan P, Greethong K, Nimmanon V. Treatment of gingival hyperpigmentation for esthetic purposes by Nd: YAG Laser: Report of 4 cases. *J Periodontol.* 2000;71:315-321.
6. Perlmutter S, Tal H. Repigmentation of the gingiva following surgical injury. *J Periodontol.* 1986;57:48-50.
7. Ahmed SK, George JP, Prabhuji MLV. Cryosurgical treatment of gingival melanin pigmentation - A 30-month follow-up case report. *Clin Adv Periodontol.* 2012;2:73-78.
8. Deepa D, Chawla A, Srivastava P. Gingival depigmentation by scalpel, diode laser and electrosurgery - A case report. *Ind J Dent Sci.* 2013;5:62-64.
9. Yeh CJ. Cryosurgical treatment of melanin-pigmented gingiva. *Oral Surg Oral Med Oral Pathol Oral Radiol Endod.* 1998;86:660-663.
10. Abraham S, Prakash P, Ambili R, Nisha, Varghese MG, Haneefa A. Gingival depigmentation with diode laser. *Journal of Society of Periodontics and Implantologists of Kerala.* 2010;4:1-18.
11. Gupta G. Management of Gingival Hyperpigmentation by Semiconductor. *J Cutan Aesthet Surg.* 2011;4:208-210.
12. Aggarwal A, Bala D, Arora S, Walia MS, Malhan S. Treatment of gingival hyperpigmentation with diode laser-An

- Esthetic Approach. Ind J Dent Sci. 2012;2:61-62.
13. Nakamura Y, Hossain M, Hirayama K, Matsumoto K. A clinical study on the removal of gingival melanin pigmentation with the CO<sub>2</sub> laser. Lasers Surg Med. 1999;25:140-147.
  14. Farnoosh AA. Treatment of gingival pigmentation and discoloration for esthetic purposes. Int J Periodon Rest Dent. 1990;10:312-319.
  15. Kaur H, Jain S, Sharma RL. Duration of reappearance of gingival melanin pigmentation after surgical removal-A Clinical Study. J Ind Soc Periodontol. 2010;14:101-105.
  16. Dummett CO, Barends G. Pigmentation of the oral tissues. A review of literature. J Periodontol. 1967;39:369-378.

---

© 2015 Narsimha Rao et al.; This is an Open Access article distributed under the terms of the Creative Commons Attribution License (<http://creativecommons.org/licenses/by/4.0>), which permits unrestricted use, distribution, and reproduction in any medium, provided the original work is properly cited.

*Peer-review history:*

*The peer review history for this paper can be accessed here:  
<http://www.sciencedomain.org/review-history.php?iid=718&id=12&aid=6955>*